

Dominik Sygut<sup>1</sup>, Stanisław Bień<sup>2</sup>, Magdalena Ziółkowska<sup>2</sup>, Stanisław Sporny<sup>1</sup>

## Immunohistochemical Expression of Androgen Receptor in Salivary Gland Cancers

<sup>1</sup>Department of Dental Pathology, Medical University, Łódź,

<sup>2</sup>Department of Otolaryngology, Head and Neck Surgery, Holy Cross Cancer Center, Kielce

**Accidental discovery of androgen receptor (AR) expression in high-grade salivary gland cancer led to evaluation of that finding. In this study we evaluated the immunohistochemical expression of AR in a series of 37 formalin-fixed, paraffin-embedded malignant salivary gland tumors using two commercially available antibodies. Nuclear immunoreactivity for AR was demonstrated in 3 of 4 salivary duct carcinomas, 2 of 7 adenocarcinomas NOS and 1 of 2 carcinoma ex pleomorphic adenoma for both antibodies. Expression of AR was evaluated semiquantatively according to Dako ER/PR pharmDx™ scoring guidelines. All positive cases came from male patients. There was no immunoreactivity seen in 13 adenoid cystic carcinomas, 7 mucoepidermoid carcinomas and 4 acinic cell carcinomas. The expression of AR in high-grade salivary gland cancers suggests a possible role for AR in the clinical management of these neoplasms.**

### Introduction

Following accidental discovery of androgen receptor (AR) expression in salivary gland cancers and a study by Kapadia and Barnes [2, 6], in which AR expression was evaluated in high grade salivary gland carcinomas, a few studies were published where that finding was confirmed [3, 5, 11, 12, 13, 16].

Salivary gland cancers are uncommon neoplasms that comprise about 0.3% of newly diagnosed malignancies worldwide [1]. The biologic behavior depends on histology, disease site and stage. Definitive treatment consists typically of surgical resection of the tumor including the tissue of salivary gland. The regional lymph nodes resection with or without postoperative radiation therapy depends on clinical and histological factors of the tumor. Chemotherapy is

generally reserved for the palliative treatment of metastatic disease or locoregional recurrences for which further surgery or radiation is not applicable [4, 8, 10, 15]. Nowadays it is becoming a part of some therapeutic protocols [7]. Despite advances in surgical techniques and reconstructive techniques, as well as the increasing use of adjuvant radiation therapy, a significant proportion of patients experience local recurrence after definitive therapy for salivary gland carcinomas [2].

Because of rarity of salivary gland cancers, there are limited clinical data to help define the role of systemic therapy in a palliative management of salivary gland cancers [7]. There is increasing interest in determining the molecular abnormalities underlying the different subtypes of salivary gland cancers, in the hopes that this will lead to the discovery of more effective, targeted therapies. The presence of estrogen receptors in normal salivary tissue and in some salivary carcinomas had led to the investigation of expression of hormonal receptors [5, 7].

There are two case reports presenting partial remissions of a parotid gland carcinoma treated with a luteinising hormone-releasing hormone analogue commonly used for metastatic prostate carcinoma [9, 14]. Further data are required to establish if androgen receptor staining in parotid tumors may be clinically useful as an indicator of susceptibility to hormonal treatment.

In this study the expression of androgen receptor is determined to evaluate their potential use as a biomarkers in the therapeutic stratification of patients with salivary gland cancers.

### Material and Methods

The selected 37 salivary gland carcinomas in form of paraffin embedded tissue blocks accessioned in Holy Cross

**TABLE 1**

Clinicopathologic findings in 37 patients with Salivary Gland Cancers presented at the study. Patients with no comment on follow-up are alive with no evidence of disease

Case No	Tumor type	Age/ Gender	Site	Follow-up (months)	Comments on follow-up
1	acinic cell carcinoma	51/M	parotid gland	168	2003-operated 3 local recurrences, free of disease
2	acinic cell carcinoma	35/F	parotid gland	38	
3	acinic cell carcinoma	51/F	parotid gland	30	
4	acinic cell carcinoma	57/M	parotid gland	18	
5	adenocarcinoma NOS	63/M	parotid gland	28	Alive with disease at 28 months, metastases, directed to chemotherapy
6	adenocarcinoma NOS	63/F	parotid gland	20	Died of disease at 20 months
7	adenocarcinoma NOS	65/M	parotid gland	24	Metastases in lung 24 months after surgery, then lost to follow-up
8	adenocarcinoma NOS	77/M	parotid gland	40	Died at 40 months
9	adenocarcinoma NOS	74/M	parotid gland	5	Metastases in lung, died of disease at 5 months
10	adenocarcinoma NOS	64/F	submandibular gland	5	Died at 5 months
11	adenocarcinoma NOS	75/M	parotid gland	4	
12	adenoid cystic carcinoma	63/F	submandibular gland	2	Lost to follow-up at 50 months with metastases to lung and liver
13	adenoid cystic carcinoma	74/M	submandibular gland	57	
14	adenoid cystic carcinoma	49/F	submandibular gland	41	
15	adenoid cystic carcinoma	57/M	submandibular gland	42	Alive with disease at 42 months, metastasis in lung
16	adenoid cystic carcinoma	49/F	submandibular gland	11	Metastases in lung and spine, died of disease at 11 months
17	adenoid cystic carcinoma	56/M	submandibular gland	14	
18	adenoid cystic carcinoma	51/M	submandibular gland	18	
19	adenoid cystic carcinoma	32/F	parotid gland	15	
20	adenoid cystic carcinoma	24/F	parotid gland	15	
21	adenoid cystic carcinoma	55/F	submandibular gland	25	
22	adenoid cystic carcinoma	32/M	submandibular gland	8	
23	adenoid cystic carcinoma	48/M	parotid gland	80	Metastases in regional lymph nodes at 72 months
24	adenoid cystic carcinoma	76/F	parotid gland	120	Alive with disease at 120 months, local recurrences
25	carcinoma ex pleomorphic adenoma	20/M	parotid gland	5	Lost to follow-up
26	carcinoma ex pleomorphic adenoma	74/F	parotid gland	5	5 months later lost to follow-up
27	mucoepidermoid carcinoma	12/F	parotid gland	54	
28	mucoepidermoid carcinoma	52/F	parotid gland	49	
29	mucoepidermoid carcinoma	48/F	parotid gland	16	
30	mucoepidermoid carcinoma	74/F	parotid gland	16	
31	mucoepidermoid carcinoma	34/F	small salivary gland	23	
32	mucoepidermoid carcinoma	29/F	small salivary gland	9	
33	mucoepidermoid carcinoma	76/M	parotid gland	10	
34	salivary duct carcinoma	76/M	parotid gland	4	Died of disease at 4 months
35	salivary duct carcinoma	69/M	parotid gland	30	Alive with disease at 30 months, metastases in lung, directed to palliative treatment
36	salivary duct carcinoma	65/M	small salivary gland	36	Local recurrences, alive with disease at 36 months
37	salivary duct carcinoma	72/F	parotid gland	38	Alive with disease at 38 months, metastasis in lung

Cancer Center's Department of Pathology, Kielce, Poland, diagnosed between January 2001 and December 2007 were used in this study. These tumors, from 18 women and 19 men between 12 and 79 years old (mean age, 55.7 years) arose in parotid, submandibular and small salivary glands. The relevant clinical features of the selected cases for the study are summarized in Table 1.

For confirmation the final histologic diagnosis and selection appropriate representative paraffin blocks for immunohistochemical analysis for AR expression all original slides from each of the cases were reviewed independently by two pathologists.

**Immunohistochemical Technique**

Serial 4-µm-thick tissue sections cut from the selected paraffin blocks were mounted individually onto charged glass slides. Additional positive control sections with known AR expression from previously prepared paraffin block containing three cores of prostate gland were mounted onto the the slides. The diameter of each core in the inner control was 4-mm. Slides with tissue sections and inner controls were dried overnight on the stretching table with temperature 58°C. Sections were deparaffinized and rehydrated before staining. All immunohistochemical staining was performed after microwave antigen retrieval, for which the tissue sections were pretreated according to

the specifications. After the slides had cooled to the room temperature. Tissue specimens were treated with 3% hydrogen peroxide for 15 minutes to quench endogenous peroxidase activity.

Tissue sections were stained immunohistochemically using commercially available monoclonal antibodies and Dako DAB+CHROMOGEN (K3468). The primary antibodies used in the study were as follows: AR (clone AR441, 1:50 dilution, DakoCytomation) and AR (clone AR27, 1:100 dilution, Novocastra). Positive controls and negative controls (omission of the primary antibody with Dako Tris-Buffered Sialine [S1968]) were run simultaneously.

Slide evaluation was performed by two pathologists using a light microscope. Immunostaining for AR was identified by brown stain confined exclusively to the nucleus. Expression of AR was evaluated semiquantatively according to Dako ER/PR pharmDx™ scoring guidelines [Interpretation manual, ER/PR pharmDx™, Pathology, Dako 2007]. Scoring was based on examination of all tumor cells on the slide. A Proportion Score (PS) was assigned representing the proportion of tumor cells with positive nuclear staining. An Intensity Score (IS) was assigned representing the average staining intensity of all positive tumor cells. A Total Score (TS) was the sum of PS plus IS (ranging from 0, 2-8). A positive result for AR was defined as  $TS \geq 3$ . (17) All scoring guidelines for ER/PR pharmDx™ are presented in Fig. 1.




Fig. 1. Allred Scoring Guidelines for ER/PR pharmDx™ taken from ER/PR pharmDx™ Interpretation Manual, Pathology Dako 2007 ([http://pri.dako.com/28252\\_er\\_pr\\_pharmdx\\_interpretation\\_manual.pdf](http://pri.dako.com/28252_er_pr_pharmdx_interpretation_manual.pdf)). In the Interpretation Manual there is a modification of the original guidelines described by D.C. Allred in 1998.

## Results

Nuclear immunoreactivity for AR was demonstrated in 3 (out of 4) cases of salivary duct carcinoma (Fig. B), 2 (out of 7) cases of adenocarcinoma NOS (Fig. D) and 1 (out of 2) case of carcinoma ex pleomorphic adenoma. The expression was observed for both Dako and Novocastra antibodies. There was no AR immunoreactivity observed in remaining 31 tumors. Each immunoreactive tumor for AR came from men. AR expression was not observed in tumors from females.

Semiquantitative evaluation according to Dako ER/PR pharmDx™ scoring guidelines of the expression of AR is summarized in Table 2. In 2 cases of salivary duct carcinomas, 2 cases of adenocarcinoma NOS and one case of carcinoma ex pleomorphic adenoma stained with Novocastra's AR the proportion of positive nuclei was smaller than stained with Dako's one. Also the intensity of expression in those cases was weaker.

The AR expression in inner controls for both antibodies was very strong (TS = 8/8).

**TABLE 2**

Semiquantitative evaluation of the AR expression in 6 cases of salivary gland cancers according to the ER/PR pharmDx™ scoring guidelines for two AR antibodies

Case No	Diagnosis	Androgen Receptor Expression					
		Dako			Novocastra		
		(PS)	(IS)	(TS)	(PS)	(IS)	(TS)
7	Adenocarcinoma NOS	5	2	7	4	1	5
9	Adenocarcinoma NOS	5	2	7	3	1	4
25	Ca ex pleomorphic adenoma	5	3	8	4	2	6
34	Salivary duct carcinoma	5	2	7	3	1	4
35	Salivary duct carcinoma	5	3	8	4	2	6
36	Salivary duct carcinoma	5	3	8	5	2	7

PS = proportion score; IS = intensity score; TS = total score.

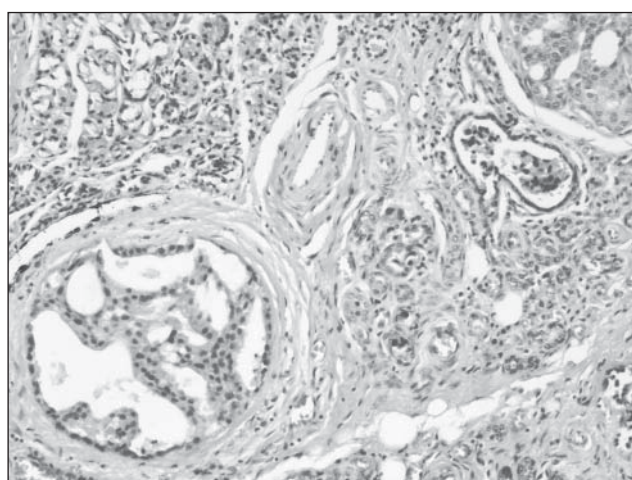


Fig. A. Salivary duct carcinoma with cribriform pattern is seen in the bottom left corner. The normal salivary gland is seen in the top left and bottom right corners of the figure. HE, magnification 100x.

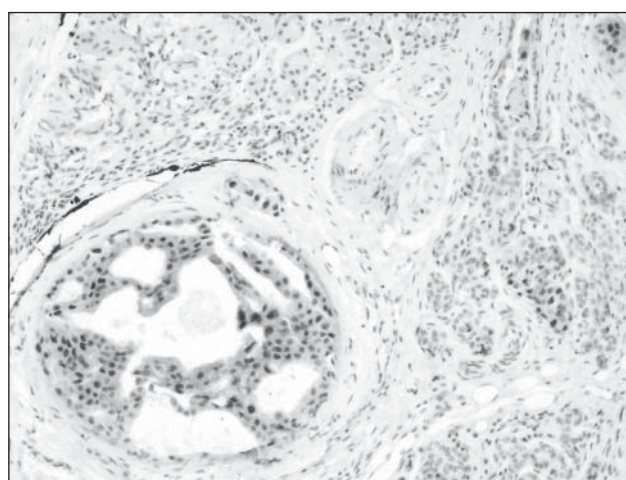


Fig. B. Strong nuclear expression of androgen receptor (TS=7) in salivary duct carcinoma. Magnification 100x.



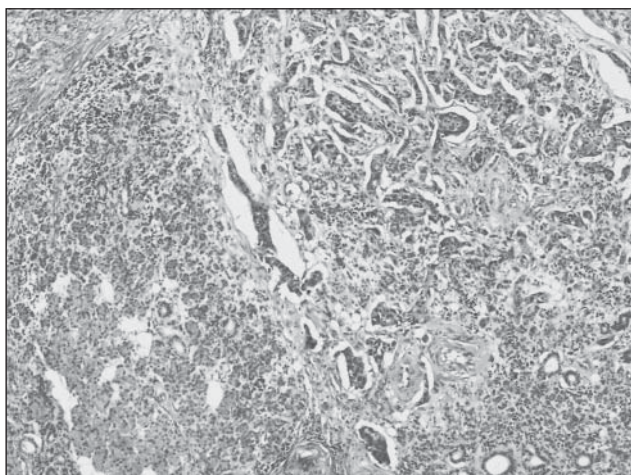


Fig. C. Adenocarcinoma NOS infiltrating salivary gland. Tumor cells infiltrating the salivary gland are seen in the top right corner of the figure. Intact, normal salivary gland – in the bottom left corner of the figure. HE, magnification 40x.

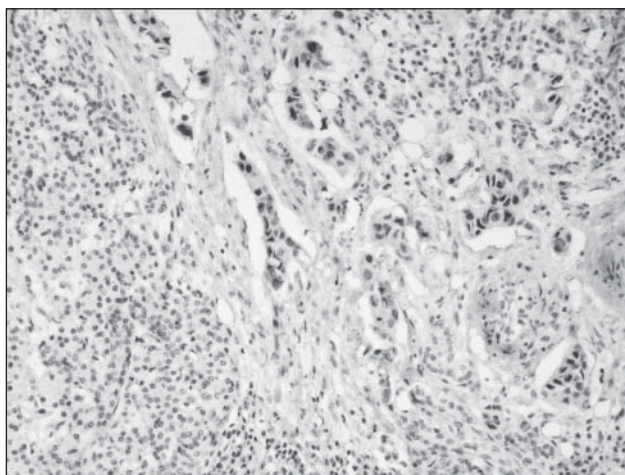


Fig. D. Strong nuclear expression of androgen receptor (TS=7) in adenocarcinoma NOS infiltrating salivary gland. Small groups of the tumor cells are scattered throughout the salivary gland. Magnification 100x.

## Discussion

Following the original paper of Kapadia and Barnes [6] a few studies describing the evaluation of AR in salivary gland carcinomas were published [3, 5, 11, 12, 13, 16]. Our study confirmed that some of high grade salivary gland carcinomas express androgen receptor. The expression was seen only in the male patients. Six of thirty seven cases of salivary gland carcinomas were immunoreactive for both Dako and Novocastra antibodies. The proportion and intensity of the expression differed between those antibodies. This observation could be taken into consideration if those patients were going to get the androgen blocking treatment.

In the literature two cases of parotid adenocarcinomas achieving a partial remission [14] and a complete remission [9] after treatment with a luteinizing hormone-releasing hormone (LHRH) analogue have been described.

Van der Hulst et al. [14] observed a remarkable regression of tumor after treatment with goserelin (which decreases testicular testosterone). He postulated that this effect is mediated through androgen receptors. Fan et al. [3] suggested that combination of flutamide or nilutamide with a luteinizing hormone-releasing hormone (LHRH) agonist as used in prostatic carcinoma might be a consideration for patients with metastatic salivary gland carcinomas when all conventional modalities fail. In 2003 Locati et al. [9] demonstrated a complete remission with androgen deprivation

therapy in a recurrent androgen receptor-expressing adenocarcinoma of a parotid gland. Because androgens play a role as both a survival and growth factor and androgen-deprivation therapy is successful in prostatic cancer, that case suggested that a similar mechanism may be implicated in AR-positive salivary gland tumors.

According to our data and literature [3, 5, 6, 11, 12, 13, 16] further evaluation of the role of AR in pathogenesis and treatment of certain malignant salivary gland tumors should be considered. Furthermore, anti-androgen therapy could be the last possible treatment for male patients with recurrent or metastatic high grade salivary gland cancers exhibiting androgen receptor when all conventional therapies fail. The evaluation of AR expression in high grade salivary gland cancers should not be troublesome because the methodology is the same as for the evaluation of the expression of other steroid hormones status like estrogen and progesterone receptors in the breast cancers.

## References

1. Barnes L, Eveson JW, Reichart P, Sidransky D: Pathology and Genetics of Head and Neck Tumours. WHO Classification of Tumours, Volume 9, 2005.
2. Chen AM, Garcia J, Bucci MK, Chan AS, Kaplan MJ, Singer MI, Phillips TL: Recurrent salivary gland carcinomas treated by surgery with or without intraoperative radiation therapy. *Head Neck* 2008 Jan, 30, 1, 2-9.

3. *Fan CY, Wang J, Barnes EL*: Expression of androgen receptor and prostatic specific markers in salivary duct carcinoma: an immunohistochemical analysis of 13 cases and review of the literature. *Am J Surg Pathol* 2000 Apr, 24, 4, 579-586.
4. *Garden AS, el-Naggar AK, Morrison WH, Callender DL, Ang KK, Peters LJ*: Postoperative radiotherapy for malignant tumors of the parotid gland. *Int J Radiat Oncol Biol Phys* 1997 Jan 1, 37, 1, 79-85.
5. *Jaehne M, Roeser K, Jaekel T, Schepers JD, Albert N, Löning T*: Clinical and immunohistologic typing of salivary duct carcinoma: a report of 50 cases. *Cancer* 2005 Jun 15, 103, 12, 2526-2533.
6. *Kapadia SB, Barnes L*: Expression of androgen receptor, gross cystic disease fluid protein, and CD44 in salivary duct carcinoma. *Mod Pathol* 1998 Nov, 11, 11, 1033-1038.
7. *Laurie SA, Licitra L*: Systemic therapy in the palliative management of advanced salivary gland cancers. *J Clin Oncol* 2006 Jun 10, 24, 17, 2673-2678.
8. *Le QT, Birdwell S, Terris DJ, Gabalski EC, Varghese A, Fee W Jr, Goffinet DR*: Postoperative irradiation of minor salivary gland malignancies of the head and neck. *Radiother Oncol* 1999 Aug, 52, 2, 165-171.
9. *Locati LD, Quattrone P, Bossi P, Marchianñ AV, Cantù G, Licitra L*: A complete remission with androgen-deprivation therapy in a recurrent androgen receptor-expressing adenocarcinoma of the parotid gland. *Ann Oncol* 2003 Aug, 14, 8, 1327-1328.
10. *Mendenhall WM, Morris CG, Amdur RJ, Werning JW, Villaret DB*: Radiotherapy alone or combined with surgery for salivary gland carcinoma. *Cancer*. 2005 Jun 15, 103, 12, 2544-2550.
11. *Moriki T, Ueta S, Takahashi T, Mitani M, Ichien M*: Salivary duct carcinoma: cytologic characteristics and application of androgen receptor immunostaining for diagnosis. *Cancer* 2001 Oct 25, 93, 5, 344-350.
12. *Nagao T, Gaffey TA, Visscher DW, Kay PA, Minato H, Serizawa H, Lewis JE*: Invasive micropapillary salivary duct carcinoma: a distinct histologic variant with biologic significance. *Am J Surg Pathol* 2004 Mar, 28, 3, 319-326.
13. *Nasser SM, Faquin WC, Dayal Y*: Expression of androgen, estrogen, and progesterone receptors in salivary gland tumors. Frequent expression of androgen receptor in a subset of malignant salivary gland tumors. *Am J Clin Pathol*. 2003 Jun, 119, 6, 801-806.
14. *van der Hulst RW, van Krieken JH, van der Kwast TH, Gerritsen JJ, Baatenburg de Jong RJ, Lycklama à Nijeholt AA, Meinders AE*: Partial remission of parotid gland carcinoma after goserelin. *Lancet*. 1994 Sep 17, 344, 8925, 817.
15. *Vander Poorten VL, Balm AJ, Hilgers FJ, Tan IB, Keus RB, Hart AA*: Stage as major long term outcome predictor in minor salivary gland carcinoma. *Cancer*. 2000 Sep 15, 89, 6, 1195-1204.
16. *Williams MD, Roberts D, Blumenschein GR Jr, Temam S, Kies MS, Rosenthal DI, Weber RS, El-Naggar AK*: Differential expression of hormonal and growth factor receptors in salivary duct carcinomas: biologic significance and potential role in therapeutic stratification of patients. *Am J Surg Pathol* 2007 Nov, 31, 11, 1645-1652.

**Address of correspondence and reprint requests to:**

Dominik Sygut  
 Full-time Post Graduate Doctoral Studies  
 Department of Dental Pathology  
 Medical University of Łódź  
 Ul. Czechosłowacka 8/10  
 92-216 Łódź  
 E-mail: dominik.sygut@onet.pl