

Krzysztof Okoń¹, Agnieszka Klimkowska¹, Anna Pawelec¹, Zygmunt Dobrowolski², Zbigniew Kohla³, Jerzy Stachura¹

Immunophenotype and Cytogenetics of Mucinous Tubular and Spindle Cell Carcinoma of the Kidney

¹Department of Pathomorphology, Jagiellonian University, Collegium Medicum,

²Department of Urology, Jagiellonian University, Collegium Medicum,

³Department of Urology, Brzesko Community Hospital

Mucinous tubular and spindle cell carcinoma (MT-SCC) of the kidney is a rare, recently described entity. The authors present three new cases. The histological picture was that of classic MTSCC, with alternating small tubules located in a mucin-containing stroma, and spindle cell areas composed of bland, monomorphic cells. On immunohistochemistry, the tumors were positive for epithelial markers, including CK7 and CK18, vimentin, CD15, AMACR, and neuroendocrine markers, such as NSE and CD57. On FISH analysis we found losses on chromosomes 1 and 8, and gains of chromosomes 7 and 17. This is the first report of this rare entity in Polish medical literature.

Introduction

Between 1992 and 2005, 775 renal tumors were diagnosed in our institution. On reviewing archive material, we found three cases consistent with the diagnosis of mucinous tubular and spindle cell carcinoma (MTSCC). This is a relatively new entity, described under various names, such as “low-grade mucinous tubular renal carcinoma” [7], “compact variant of papillary carcinoma without papillae” [6], and included only in the most recent WHO classification textbook [5]. It has a characteristic morphologic picture, but its immunohistochemical and molecular features differ between reports. Any new descriptions are thus expanding our understanding of this entity.

Material and Methods

The material consisted of MTSCC cases found among 775 renal tumors diagnosed in our institution from 1992 to 2005. The material was formalin-fixed, routinely processed and paraffin-embedded. From the tissue blocks, 3µm sections were prepared and stained with hematoxylin-eosin. Cases with extensive necrosis, cystic tumors with tiny foci of neoplastic epithelium and secondary tumors were excluded from consideration. All the cases were reclassified according to the WHO system [5]. For immunohistochemistry, the standard staining protocol was used. Briefly, the slides were dewaxed, rehydrated and incubated in 3% peroxide solution for 10 minutes to block endogenous peroxidase activity. Antigen retrieval was carried out by microwaving in citrate buffer (0.2% citric acid titrated to pH 6.0 with 2N NaOH) at 750 W for 3x5 minutes. Primary antibodies are listed in Table 1. The ENVISION (DAKO, Denmark) detection system was used. 3-amino-9-ethyl-carbasole (DAKO, Denmark) was used as the chromogen. The slides were counterstained with Mayer hematoxylin (DAKO, Denmark). All the tumors were restaged by the more recent AJCC and traditional Robson systems [1]. On restaging, three cases of tumors composed of tiny tubules with small collections of mucin and foci of regular spindle cells were found. These tumors constitute the subject of the present investigation.

For FISH studies, hematoxylin-eosin stained sections were reviewed and in each case one section containing representative and well-preserved carcinoma tissue was select-

TABLE 1

Antibodies used for immunohistochemical studies

Specificity	Manufacturer	Clone	Dilution
CK7	DAKO	OV-TL12/30	1:50
CK-HMW	DAKO	34 β E12	1:50
CK 5/6	DAKO	D5/16B4	1:50
CK18	DAKO	DC10	1:50
CK19	DAKO	RCK108	1:50
CK20	DAKO	Ks20.8	1:50
CD10	Novocastra	56C6	1:50
CD15	Novocastra	BY87	1:50
CD56	Novocastra	1B6	1:50
CD57	Novocastra	CD564	1:50
VIM	DAKO	V9	1:50
EMA	DAKO	E29	1:100
AMACR	Abcam	(polyclonal)	stock
c-KIT	DAKO	(polyclonal)	1:25
NSE	DAKO	BSS/NC/IV-H14	1:100
chromogranin	DAKO	(polyclonal)	1:100
synaptophysin	DAKO	(polyclonal)	1:50
e-cadherin	Biogenex	HU-390-UC	1:20
RCC	Abcam	PN-15	1:25
HMB-45	DAKO	HMB45	1:50
SMA	DAKO	1A4	1:50
GPC3	Biomosaics	1G12	stock

ed. Three- μ m thick sections were prepared from the paraffin blocks. Fluorescent hybridization in situ was performed using the FISH CEP VYSIS Assay kit (Vysis Inc., Downers Grove, USA) following the manufacturer's instructions. Briefly, the sections were deparaffinized, washed twice in fresh xylene, 10 minutes per wash, immersed twice in 100% ethanol for 5 minutes, and air-dried. Subsequently, the slides were incubated in 0.2N hydrochloric acid for 20 minutes, washed in Visys Wash Buffer and placed in Pre-treatment Solution (Vysis Inc., Downers Grove, USA) at 80°C for 30 minutes, then washed again in distilled water and washed twice in Visys Wash Buffer for 5 minutes. The slides were protease-digested at 37°C for 38 min, washed twice in Visys Wash Buffer for 5 minutes, air-dried and dehydrated in a series of alcohols. Subsequently, following the addition of DAPI solution, the digestion quality was controlled under a fluorescence microscope and DAPI was removed by rinsing. The hybridization solution contained 1 μ l of probes, 2 μ l of water and 7 μ l of CEP Hybridization Buffer. The following probes were used: CEP1 – Spectrum Orange and CEP8 – SpectrumGreen, as well as CEP17 – SpectrumOrange and CEP7 – SpectrumGreen. An aliquot of 10 μ l of probe solution was placed on the surface of each preparation, closed with a cover glass, sealed and dried at

37°C. Denaturation was carried out at 72°C in a MP16 hybridization device (GENOS, Łódź, Poland) for 5 minutes. Hybridization was carried out at 37°C over night. Following the removal of sealant and cover glass, the preparations were rinsed in post-hybridization Wash Buffer (2x sodium salt citrate, 0.3% NP-40, pH 7.0–7.5) at room temperature, and subsequently in post-hybridization Wash Buffer at 73°C for 2 minutes. The preparations were then air-dried, covered with 10 μ l DAPI solution applied in drops and closed with cover slips. The preparations were stored in the dark at –20°C and warmed to room temperature for evaluation. The staining results were evaluated under an Axioscop microscope using a 100 \times PlanNeofluar lens (Carl Zeiss AG, Oberkochen, Germany), equipped with appropriate filter sets. For each evaluated field of view, photographs were taken with a ZVS-47DE digital camera (Carl Zeiss AG, Oberkochen, Germany) and entered into the AnalySIS 3.2 pro image analysis system (Soft Imaging System GmbH, Germany). Images of Spectrum Green (green channel), Spectrum Orange (red channel) and DAPI (blue channel) were combined into RGB color images. These were saved on a hard disk. In the evaluation step, the FISH signals in individual nuclei were counted. The cells that were not properly separated from the others, or not well preserved, were excluded from the evaluation. For each experiment, a minimum of 100 nuclei was counted. The average number of signals per cell was used as the result.

Results

Case 1 was a 33-year old female. The material received for evaluation consisted of a bisected kidney weighting 310 g. The tumor was 6.5 cm in diameter, solid and yellowish. The lesion was composed of spindle cells and tubular/trabecular areas. Although there was no evidence of crossing the capsule on gross examination, histologically, the cancer crossed the renal capsule and entered into the perirenal fat tissue and renal hilus. Venous invasion was also present. The diagnosis given at the time was “intermediately differentiated adenocarcinoma”, without type specification. Outside the main tumor mass, the renal parenchyma showed signs of chronic pyelonephritis. No follow-up information was available in this case.

Case 2 was a 56-year old asymptomatic male. The tumor was detected by an abdominal US scan during a medical work-up. Thin needle aspiration biopsy was performed, revealing carcinoma cells. Papillary RCC was the diagnosis suggested as most likely. The nephrectomy specimen weighting 276 g contained a 2.5 cm, well-delimited tumor, separated from the surrounding parenchyma by a thin pseu-

TABLE 2

Results of the immunohistochemistry

	Case 1	Case 2	Case 3
CK7	-	+	+
CK-HMW	-	+	+
CK 5/6	-	-	-
CK18	+/-	+	+/-
CK19	-	-	+
CK20	-	-	-
CD10	-	-	+
CD15	+/-	+/-	+/-
NCAM	-	-	-
CD57	+/-	+	+/-
VIM	+	+	+
EMA	-	+	+
AMACR	+	+	+/-
c-KIT	+/-	+/-	+/-
NSE	+	+	+
chromogranin	+/-	-	+/-
synaptophysin	-	-	-
e-cadherin	-	-	-
RCC	+	+/-	+/-
HMB-45	n/d	n/d	-
SMA	n/d	n/d	-
GPC3	-	n/d	n/d

N/D – not done

docapsule. On microscopic examination, the lesion was composed of delicate tubules consisting of cuboid, regular epithelial cells with slightly basophilic mucoid substance. There was also a minor spindle cell component, located




Fig. 1. Case 2. Predominantly tubular pattern composed of elongated tubules and trabeculae of small, cuboid cells with round, regular nuclei, H+E, lens magnification 20x.

TABLE 3

Results of the FISH studies

	cep1	cep8	cep17	cep7
Case 1	1.40	2.00	2.28	2.23
Case 2	1.55	1.42	2.71	2.37
Case 3	1.82	2.04	2.16	2.35

mainly on the periphery. The tumor was limited to the kidney, with no signs of extrarenal extension. The diagnosis was “tubulopapillary adenocarcinoma”. At the moment, over 6 years after nephrectomy, the patient is well and without evidence of the disease.

Case 3 was a 29-year old, asymptomatic, otherwise healthy woman. The tumor was detected by a screening abdominal US scan. The postoperative period was uneventful. The nephrectomy specimen consisted of a bisected kidney 12x6x4 cm. The tumor 5cm in diameter was located in the upper pole, whitish and solid. The lesion was composed of cuboid cells with solid, papillary and tubular growth patterns. In some cells the cytoplasm was clear, in others eosinophilic. Foamy macrophages were present focally. Spindle cell areas were also present. No extrarenal extension was evident, either grossly or microscopically. The lesion was diagnosed an unclassified renal cell carcinoma. The patient is under control and at present is in a good condition, without evidence of disease. The period of follow-up is 20 months.

Immunohistochemically, the above described lesions showed expression of vimentin, epithelial markers, including HMW CK, CK18 and CK7, a weak expression of

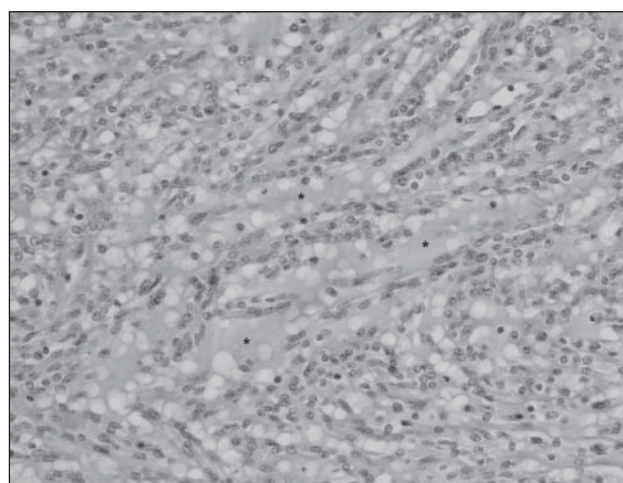


Fig. 2. Case 2. Area with mucin (*) separating trabeculae of small, cuboid cells with round, regular nuclei, H+E, lens magnification 40x.

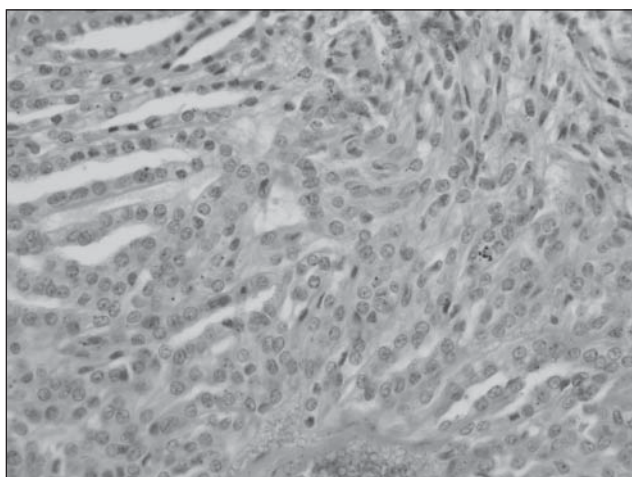


Fig. 3.
Case 3. Transition of tubular to spindle cell area. H+E
80x.

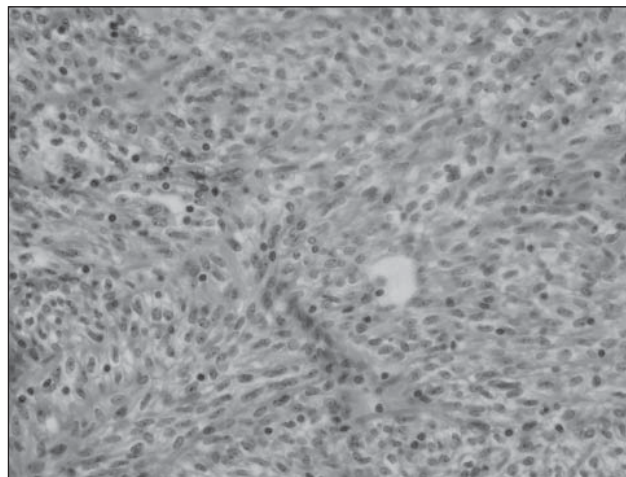


Fig. 4.
Case 3. Spindle cell area. Quite regular, elongated cells.
H+E 60x.

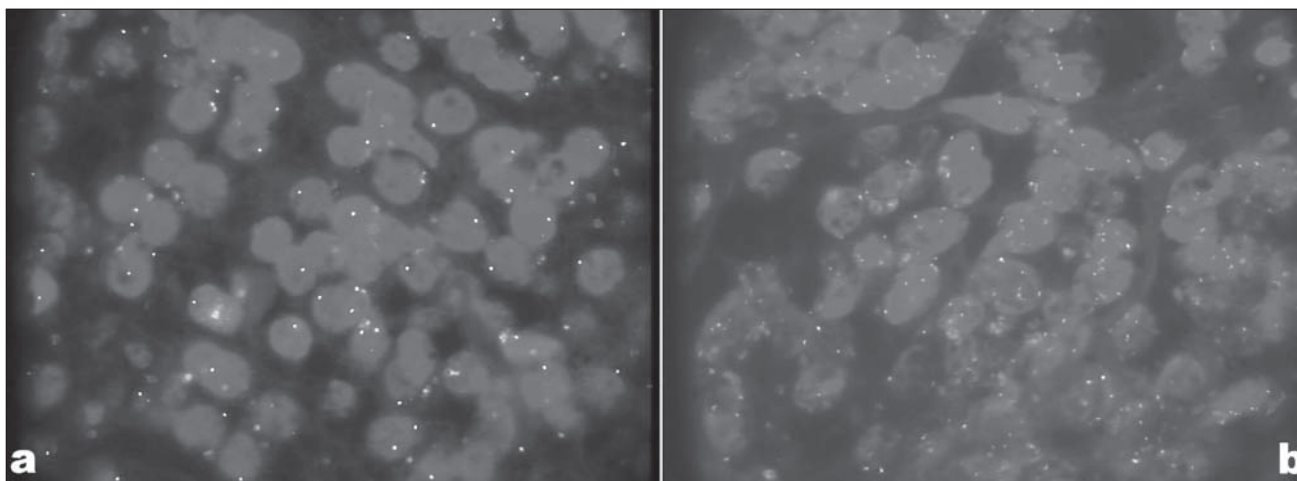


Fig. 5.
Case 2, FISH results. a) chromosome 1 (red) & 8 (green) probes. Several cells contain single signals only. b) chromosome 7 (green) & 17 (red) probes. Additional signals in some of the cells. Lens magnification 100x.

CD15, but not CD10. Such a pattern of expression demonstrates rather features of distal nephron differentiation, including the connecting duct. Some neuroendocrine features were also evident, as the tumors were positive for NSE and CD57, but not for synaptophysin or NCAM. A weak reaction for chromogranin was present in Cases 1 and 3. All the results of the immunohistochemical studies are shown in Table 2.

On FISH, in all the three cases, losses on chromosome 1 were seen. Case 2 showed also loss at chromosome 8. An increased copy number was observed on chromosomes 7 and 17. The results are shown in Table 3 and Fig. 6.

Discussion

Mucinous tubular and spindle cell carcinoma of the kidney (MTSCC) is a relatively new entity, first described in the late '90s. It is included in the new WHO classification [4, 5]. At times, this tumor is misdiagnosed as papillary renal cell carcinoma, metanephric adenoma, unclassified or sarcomatoid carcinoma [4, 7, 8, 9]. Mistaking a low grade MTSCC for a highly aggressive tumor with sarcomatoid features is relatively likely; this misdiagnosis may be of a high clinical importance. More typical cases of papillary carcinomas showing mucin secretion were also described

by Val-Bernal et al. [20]. It is noteworthy that these cases showed, similarly as MTSCC, markers of both proximal and distal nephron differentiation.

In the majority of the published series, MTSCC shows an obvious female predominance. Although it is usually large, MTSCC is a low-grade cancer, with few reports of progression. The histological structure is quite characteristic, with tubular structures alternating with areas of low-grade spindle cells and various amount of mucinous secretion. The cells composing tubules are cuboid and rather small, with bland nuclei and tiny nucleoli. Spindle cells are also uniform with bland nuclei. The number of mitotic figures is very small to none [3, 5, 7, 8, 9, 11, 16]. Alcian blue and PAS may be positive in the mucinous areas [2]. In half of the cases, tubular areas may markedly predominate in the picture, resulting in a picture quite similar to classic papillary renal cell carcinoma [8]. In Fine et al. series, 7 of 17 cases were mucin-poor. Papillary formations, foamy macrophages, clear cells and cells with oncocyctic features were also described [8]. Shen et al. [17] stress the similarity of MTSCC to typical papillary RCC. They have seen compressed papillary growth in a large majority of cases; also the presence of foamy macrophages and nuclear features were similar in both tumors. As stated above, a very important differential diagnosis may be RCC, mostly papillary, with sarcomatoid transformation [14]. Kuroda et al. [11] described tiny foci of clear cell differentiation. In the paper by Ortega et al., cytological features of MTSCC useful for differential diagnosis are described [13].

Clinically, the lesion may be asymptomatic and detected incidentally or present with hematuria or flank pain [2, 7, 9, 12]. In the series described by Ferlicot et al. [6], the patients were aged 21 to 81 years (mean 53). All the tumors were solitary. Of 15 patients, five were lost from observation, nine were alive without evidence of disease, and one died, but the cause of death remained uncertain. The case presented by Ortega et al. [13] was a tumor 7cm in diameter, which was limited to the kidney. The three patients described by Brandal et al. [3] were aged 19, 52 and 80 years. All their tumors were limited to the kidney and sized 12, 9.5 and 5.5 cm. In Shen's series [17], the predominance of females to males was 3:1 and the patients showed a broad age range (35-73 years, mean 56). All three cases presented by Aubert et al. [2] were females, aged 36 to 80 years.

In previous reports, complex chromosomal changes were shown, with both chromosome losses on chromosome 1, 4, 6, 8, 13 and 14, and gains of chromosome 7, 11, 16 and 17 [5]. Ferlicot et al. [6, 7] published 15 cases; two were studied by comparative genomic hybridization. In one case, multiple chromosomal changes were seen,

including loss of 1, 4, 6, 11, 8, 13, 14, 15, 18 and 22, but no trisomy 7 and 17 nor loss of VHL locus on 3p. In the other two cases, there were losses of chromosomes 1, 6, 11, 14, 22 and gain on 15. Brandal et al. [3] described in details three cases of MTSCC. They found a hypodiploid pattern in two, and hypertriploid in one case. On FISH, hypodiploid tumors had mixed, disomic and monosomic karyotypes, whereas the near-triploid tumor had a dominant trisomic pattern. On CGH, one tumor showed no abnormalities, but the other did. The alterations were gains of chromosomes 10, 16, 17, 19, 20 and 21, and losses of chromosomes 3, 8, 9 and 13. Rakozy et al. [16] reported losses of chromosomes 1, 4, 6, 8, 9, 13, 14, 15 and 22 combined, in some cases, with loss of X chromosome. They interpreted these chromosomal changes as similar to those occurring in chromophobe renal cell carcinoma. In summary, no single characteristic pattern of changes is known, thus molecular studies offer no diagnostic benefit over microscopic examination. Our results show the greatest degree of consistence with the results of Srigley et al. [19].

On immunohistochemistry, MTSCC shows a complex phenotype, with somehow contradictory results in various series. Generally, MTSCC were shown to be positive for various cytokeratins, EMA, vimentin, and CD15 [5]. Cases presented by Leroy et al. [12] were positive for cytokeratin, vimentin and e-cadherin, and focally for CK7, EMA and HMW-CK. Staining for CD15 and *Ulex europaeus* was negative. Fine et al. reported positivity for CK7, AMACR and claudin-7 in most of the examined cases [8]. Ortega et al. [13] saw positivity for AE1-AE3, CK18, vimentin, but a weak reaction for EMA and CK19. The cases described by Aubert et al. were positive for pan-cytokeratin, CK19, E-cadherin in tubular areas, and focally for 34 β E12. Staining for CAE, *Ulex europaeus*, CD10 and CD15 were negative [2]. Ferlicot et al. [6] noted positivity for EMA, AE1/AE3, CK7, CK19, E-cadherin and AMACR, but not for CD10, and interpreted this as evidence for distal nephron origin. Skinnider and Parwani are of similar opinion [15, 18]. Particularly, the loop of Henle was suggested as the differentiation point [12, 15, 19]. On the other hand, Shen et al. [17] believe MTSCC is rather a proximal nephron derived tumor, and think it may be a special variant of papillary RCC. This assumption is based on the reactivity for RCC antigen, AMACR, CD15 and CK7. CD10 and kidney specific cadherin were positive in only a minor portion of cases. Also Paner et al. [14] have found the immunohistochemical pattern to be overlapping with papillary RCC, with positivity for AMACR, CK7 and EMA in the vast majority of. Rakozy et al. [16] believe that MTSCC is derived from the collective ducts. On immunohistochemistry, they saw positive

reactions for EMA, PNA, CK 8, 18 and 19, as well as vimentin. The tumors were negative for Ulex europeus, RCC antigen and villin.

According to Brandal et al. [3], MTSCC is positive for both proximal and distal nephron markers. The possible cell of origin might be a pluripotential cell differentiating towards different parts of the nephron.

Jung et al. [10] described positivity of MTSCC for neuroendocrine markers, such as NSE, chromogranin and synaptophysin. Their tumors were also positive for cytokeratins, both of low and high molecular weight, CK7, EMA, E-cadherin and vimentin. The issue of neuroendocrine differentiation is reinforced by electron microscopy analysis, which showed dense-core granules. Also Kuroda et al. [11] saw neuroendocrine differentiation in the case they described. Their tumor was positive for chromogranin, but also focally for NSE or CD57. On electron microscopy, there were dense core granules. The other markers expressed were CK18, CK19, CD9, EMA; no reactivity was present for CD10, synaptophysin, CK-HMW, or E-cadherin. In the Gaafar's material, the tumors were positive for EMA, vimentin, CK AE1/3. The reactions for CK7 and 19 were focally positive. CK8, CK18, CK20, villin, CD10, Ki67, p53, chromogranin, synaptophysin and CD57 were negative [9].

In cases shown by Ferlicot et al. [6] no oncological failures were present; also none of Shen et al. [17] patients died of the disease. Of the four cases described by Gaafar, all the patients are alive and disease-free [9], similarly as are all patients studied by Aubert et al. [2].

Brandal [3] believes that the low proliferative activity (Ki67 index below 5%) may be in part responsible for the good prognosis.

In summary, MTSCC is a rare tumor of quite distinct morphology. However, its immunohistochemical characteristics, molecular features and histogenesis need further studies. The present report is the first description in the Polish literature.

References:

1. *American Joint Committee on Cancer: Kidney*. In: Greene FL, Page DL, Fleming ID, Fritz A, Balch CM, Haller DG, Morrow M Ed: AJCC Cancer Staging Manual. Springer Verlag 2002, 323-328.
2. *Aubert S, Duchene F, Augusto D, Llinares K et al*: Low-grade tubular myxoid renal tumors: a clinicopathological study of 3 cases. *Int J Surg Pathol* 2004, 12, 179-183.
3. *Brandal P, Lie AK, Bassarova A, Svindland A et al*: Genomic aberrations in mucinous tubular and spindle cell renal cell carcinomas. *Mod Pathol* 2006, 19, 186-194.
4. *Eble JN*: Mucinous tubular and spindle cell carcinoma and post-neuroblastoma carcinoma: newly recognised entities in the renal cell carcinoma family. *Pathology* 2003, 35, 499-504.
5. *Eble JN, Sauter G, Epstein JI*: Tumours of the kidney. In: Eble JN, Sauter G, Epstein JI Ed.: WHO Classification of Tumours: Pathology and Genetics of Tumours of the Urinary System and Male Genital Organs (World Health Organization Classification of Tumours). International Agency for Research on Cancer 2004, 9-88.
6. *Ferlicot S, Allory Y, Comp erat E, Mege-Lechevalier F et al*: Mucinous tubular and spindle cell carcinoma: a report of 15 cases and a review of the literature. *Virchows Arch* 2005, 447, 978-983.
7. *Ferlicot S, Lupo A, Lazure T, Bedossa P et al*: A novel entity: low-grade mucinous tubular renal carcinoma. *Histopathology* 2005, 47, 218-219.
8. *Fine SW, Argani P, DeMarzo AM, Delahunt B et al*: Expanding the histologic spectrum of mucinous tubular and spindle cell carcinoma of the kidney. *Am J Surg Pathol* 2006, 30, 1554-1560.
9. *Gaafar A, Valenti C, Echevarria C, Laforga JB et al*: Renal mucinous and tubular spindle cell carcinoma: a clinicopathological study of 4 cases. *Ann Saudi Med* 2006, 26, 466-470.
10. *Jung SJ, Yoon HK, Chung JI, Ayala AG et al*: Mucinous tubular and spindle cell carcinoma of the kidney with neuroendocrine differentiation: report of two cases. *Am J Clin Pathol* 2006, 125, 99-104.
11. *Kuroda N, Nakamura S, Miyazaki E, Hayashi Y et al*: Low-grade tubular-mucinous renal neoplasm with neuroendocrine differentiation: a histological, immunohistochemical and ultrastructural study. *Pathol Int* 2004, 54, 201-207.
12. *Leroy X, Aubert S, Gossein B*: Low-grade myxoid renal epithelial neoplasms with distal nephron differentiation: a distinct clinicopathologic entity? *Hum Pathol* 2002, 33, 574-5; author reply 575-576.
13. *Ortega JA, Solano JG, Perez-Guillermo M*: Cytologic aspect of mucinous tubular and spindle-cell renal carcinoma in fine-needle aspirates. *Diagn Cytopathol* 2006, 34, 660-662.
14. *Paner GP, Srigley JR, Radhakrishnan A, Cohen C et al*: Immunohistochemical analysis of mucinous tubular and spindle cell carcinoma and papillary renal cell carcinoma of the kidney: significant immunophenotypic overlap warrants diagnostic caution. *Am J Surg Pathol* 2006, 30, 13-19.
15. *Parwani AV, Husain AN, Epstein JI, Beckwith JB et al*: Low-grade myxoid renal epithelial neoplasms with distal nephron differentiation. *Hum Pathol* 2001, 32, 506-512.

16. *Rakozy C, Schmahl GE, Bogner S, Storkel S*: Low-grade tubular-mucinous renal neoplasms: morphologic, immunohistochemical, and genetic features. *Mod Pathol* 2002, 15, 1162-1171.
17. *Shen SS, Ro JY, Tamboli P, Truong LD et al*: Mucinous tubular and spindle cell carcinoma of kidney is probably a variant of papillary renal cell carcinoma with spindle cell features. *Ann Diagn Pathol* 2007, 11, 13-21.
18. *Skinnider BF, Folpe AL, Hennigar RA, Lim SD et al*: Distribution of cytokeratins and vimentin in adult renal neoplasms and normal renal tissue: potential utility of a cytokeratin antibody panel in the differential diagnosis of renal tumors. *Am J Surg Pathol* 2005, 29, 747-754.
19. *Srigley JR, Eble JN, Grignon DJ*: Unusual renal cell carcinoma (RCC) with prominent spindle cell change possibly related to the loop of Henle [abstract]. *Mod Pathol* 1999, 12, 107A.
20. *Val-Bernal JF, Gomez-Roman JJ, Vallina T, Villoria F et al*: Papillary (chromophil) renal cell carcinoma with mucinous secretion. *Pathol Res Pract* 1999, 195, 11-17.

Address for correspondence and reprints request to:

Dr Krzysztof Okoń
Department of Pathomorphology
ul. Grzegórzecka 16
31-531 Kraków