

Henryk Sośnik¹, Katarzyna Sośnik¹, Agnieszka Hałoń²

The Pathomorphology of Bartholin's Gland. Analysis of Surgical Data

¹Department of Pathomorphology, Regional Specialistic Hospital, Wrocław,

²Department of Pathological Anatomy, Silesian Piasts University of Medicine in Wrocław

Medline data did not reveal any statistical approach to Bartholin's gland pathomorphological lesions, especially when the social aspect was considered.

Objectives. To complete knowledge and data according to this subject on the basis of own surgical material analysis.

Microscopic examinations of histopathological 5 µm thick specimens stained with hematoxylin-eosin and in selected cases with histochemical and immunohistochemical methods on 104 Bartholin's glands taken from 103 female patients in age of 39.4 ± 9.6 . Retention cysts, suppurating lesions (abscesses), extrauterine endometriosis and neoplasms were separated from obtained samples. Localization of lesions, the patients' age and education status were determined. $P < 0,05$ was considered as statistically significant.

Retention cysts were observed in 84.6% of cases, abscesses in 10.6%, extrauterine endometriosis in 2% and neoplasms in nearly 3% of patients. In 54.1% of cases the lesion was localized on the left side, in 45.9% on the right. 17.2% of female patients presented with university education, 29.9% with elementary education, while 52.9% with secondary education. The average age of operated patients amounted to 33 ± 9.8 years in case of university education, being significantly lower as compared to the average age of secondary (40.5 ± 7 years) and elementary (42.4 ± 12 years) education ($p < 0.01$ and $p < 0.02$ respectively). 47.7% of retention cysts demonstrated various degrees of inflammatory infiltration. However, the anatomical variability of the ductal and glandular epithelium was higher in cases of non-inflammatory cysts. Considering three Bartholin's gland neoplasms, two were diagnosed as adenocarcinomas and one as a fibromyoma. All of them were observed in female patients with a rare blood type (twice Rh-minus and once AB Rh-plus). There was no significant relationship between the type of pathomorphological lesions and age of

operated patients, in spite of the fact that the lowest mean age was observed in woman with endometriosis while the highest in those with neoplasms.

The pathology of Bartholin's gland mostly concerns female patients with secondary education. However, early diagnosis is associated with patients with university education. Thus, further investigations considering the statistical analysis of Bartholin's gland neoplasms in order to determine the possible relationship between blood type antigens and neoplasm development are required.

Introduction

Most tumors of the pudendo-vaginal region belong to cysts and abscesses of Bartholin's gland [12]. Any obturation of the external duct, the rarest cause to be connected with vulvo-vaginal surgery [19], may lead to form cysts. They can be infected with anaerobic and aerobic bacteria. Anaerobic germs were found in 32%–48.4% [3,15], and according to others [2] even in 90% of studied cases. Chlamydia trachomatis appeared in 30% [21], and Gonococci in 30.4% [7] of investigated Bartholin's abscesses. In single cases evaluation of the Bartholin's gland aspirate revealed Streptococcus pneumonia [16, 20].

Bartholin's gland diseases are quite common problem in clinical practice, but in literature we could find only single case reports of benign [9] and malignant neoplasms [8, 10, 11, 17] or at least some clinical analyses of larger series of Bartholin's gland neoplasms [1, 4, 5, 6, 13]. We also found some descriptions of external endometriosis [14, 18], but in the Medline databases there was lack of statistical analysis of pathomorphological changes in the mentioned gland, especially when the social aspect was considered. Thus, the goal of our study was to see if there is any connection between the kind and intensity of the morphological

changes in the excised glands and the age of the operated on patients. We assumed too, the intensity of the changes might have been results of insufficient therapy, probably connected with low self-awareness. Thus we accepted the education level of the patients as a counterpart of it.

Material and Methods

In years 1984–2002 in Department of Pathomorphology, Wrocław Regional Specialistic Hospital, 104 Bartholin's glands surgically obtained from 103 female patients in age 19–74 years (mean age: 39.4 ± 9.6 ; median age: 39) were examined. 5 μ m thick tissue samples from paraffin blocks were typical hematoxylin-eosin stained and in cases of neoplasms additionally histochemical (alcian blue) and immunohistochemical methods were used. Data on female patients age, localization of lesion and education status were obtained from archives files and clinical records. Statistical analysis and correlations between evaluated parameters were assessed using Chi-square and T-student tests. $P < 0.05$ was considered as statistically significant.

Results

Results are presented in Table 1 and 2. In 54.1% of cases the lesion was localized on the left side, in 45.9% on the right. Different type of retention cysts were observed in 84.6% of cases and in 47.7% of them various inflammatory infiltration were reported. Benign and malignant neoplasms were observed in nearly 3% of patients and extrauterine endometriosis in 2%. Female students or patients with university education constitute 17.2% of cases, 29.9% of female patients presented with elementary education, and

52.9% with secondary education. The average age of operated patients amounted to 33 ± 9.8 years in case of university education, being significantly lower as compared to the average age of secondary (40.5 ± 6.8 years) ($p < 0.01$) and elementary (42.4 ± 12.2 years) ($p < 0.02$) education. There was no significant relationship between the type of pathomorphological lesions and age of operated patients ($p < 0.95$), while the lowest mean age was observed in women with endometriosis (33 ± 4 years), higher in patients with retention cysts (38.3 ± 8.7 years), and the highest in those with neoplasms (49.3 ± 5.3 years).

Histopathological examinations of Bartholin's glands' retention cysts demonstrated various degrees of inflammatory infiltration (47.7% of all cysts). Weak inflammatory infiltration was observed in 62%, intense in 31%, while moderate only just in 7% of cysts. Massive, chronic, xanthomatous and fibrous inflammatory process were diagnosed in 55.6% patients with secondary education, 33.3% of patients with elementary education and barely in 11.11% of females with university education.

Morphology of the cysts' lining ductal and glandular epithelium demonstrated conspicuous variability, but was considerable higher in cases of non-inflammatory cysts than in inflammatory lesions. Stratified squamous epithelium was demonstrated twice more often in non-inflammatory cysts (26%) than in inflammatory cysts (14%). Then pseudostratified mucus-secreting columnar epithelium was found four times more often in inflammatory cysts (26%) than in non-inflammatory cysts (6.5%). Pseudostratified mucus-secreting columnar epithelium alternatively with simple cuboid epithelium occurred in 25% of non-inflammatory and only just in 19% of inflammatory cysts. Similar percentages of composition of mucus-secreting columnar epithelium with stratified squamous epithelium (about 13–15% for inflammatory and non-inflammatory cysts) and

TABLE 1

Material classification according to the type of pathological lesions considering the side of the body

Type of lesion	N	%	Body side				Lack of information	
			Left		Right		N	%
			N	%	N	%		
Non-inflammatory retention cyst	46	44,23	21	45,7	18	39,1	7	15,2
Inflammatory retention cyst	42	40,38	18	42,9	16	38,1	8	19
Chronic massive xanthomatous bartholinitis	11	10,58	4	36,4	4	36,4	3	27,2
Endometriosis	2	1,92	2	100	0	0	–	–
Benign neoplasms	1	0,96	1	100	0	0	–	–
Malignant neoplasms	2	1,92	1	50	1	50	–	–

Explanations: N – number of cases, % – percentage of cases

TABLE 2

Education and age of 103 operated patients diagnosed of Bartholin's gland pathology

Study group	N	%	Age of operated patients		
			Min.	Max.	x ± SD
University education	15	17,24	19	50	33,07 ± 9,77
Secondary education	46	52,87	22	57	40,50 ± 6,80
Elementary education	26	29,89	21	74	42,40 ± 12,23
Lack of information	16	15,53	23	54	37,13 ± 8,54

Explanations: N – number of cases, % – percentage of cases

pseudostratified mucus-secreting columnar epithelium with focal squamous metaplasia where the mucus-secreting epithelial cells lining the glandular epithelium are replaced by stratified squamous epithelium (26% for each one) were observed.

Extrauterine endometriosis was diagnosed in two cases. Benign neoplasm namely hialinizing fibroleiomyoma (positive staining for vimentin, desmin and muscle – specific actin, and negative for S-100) was

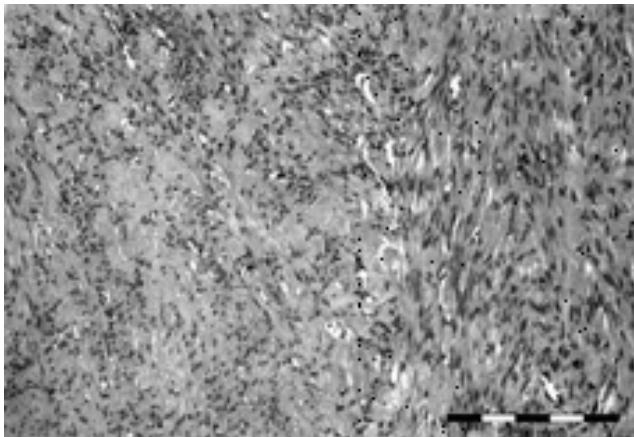


Fig. 1. Fibroleiomyoma. HE staining. Low-power magnification.

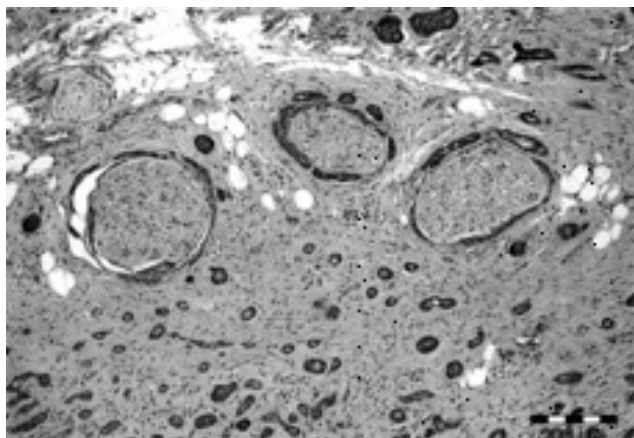


Fig. 2. Perineural invasion of typical Bartholin's gland adenoid cystic carcinoma. HE, low-grade magnification.

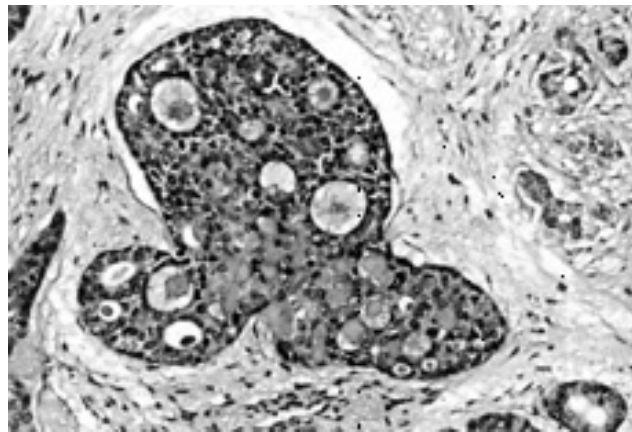


Fig. 3. Histopathological pattern of adenoid cystic carcinoma. Alcian blue staining, medium-power magnification.

diagnosed once, in 52-year-old women, one birth in time, one abortion, without important past medical history, with blood type "0" Rh-minus. Enucleation of well circumscribed, grey-white solid tumor measuring 5 × 4 × 3 cm after vestibule of vagina mucosa incision was performed (Fig. 1). In 42-year-old patient with blood type "AB" Rh-plus right Bartholin's gland adenoid cystic carcinoma 1.5 cm in size was diagnosed (Fig. 2). Third tumor was found in 54-year-old woman with blood type "0" Rh-minus, who undergo cholecystectomy and partial gastrectomy due to gastric ulcer in the past. She suffered from acute pain in left groin for three weeks and physical examination revealed solid tumor in Bartholin's gland area. Enucleation of white tumor with cystic change and infiltrating extension measuring 2.5 × 2 × 1 cm was performed and adenoid cystic carcinoma was microscopically diagnosed (Fig. 3). Tumors presented identical histopathological pattern, perineural and adjacent muscles invasion were observed in both cases. Gland-like spaces ("pseudocysts") filled with homogeneous eosinophilic material consisting of reduplicated basal lamina material and mucin produced by the tumor cells showed PAS-positive reaction, positive alcian blue and mucicarmine staining.

Discussion

Analysis of own material revealed that pathology of Bartholin's gland mostly concerns female patients with secondary education, but early diagnosis is associated with patients with university education. From the clinician's viewpoint Bartholin's gland pathology is associated with sexual activity. Practical questions originate from results are: if it is in fact earlier onset of sexual activity in females with academic status or rather higher than in other social groups notice of necessity to intensive treatment. In presented study the authors demonstrated that the most common Bartholin's gland pathology were retention cysts. Above-mentioned problem was three times more often diagnosed in women with secondary education (49.4%) and twice more often with elementary (34.12%) compared with university educated patients (16.47%). Inflammatory cysts (including cystic chronic abscesses) were observed in women with elementary as well as with university education (33.3% and 15.56% respectively). Non-inflammatory cysts were diagnosed in these social group similarly (35% and 17.5% respectively). However, among women with secondary education inflammatory lesions prevailed non-inflammatory (51.11% versus 47.5%).

There is important notification in literature about the rare incidence of Bartholin's gland neoplasms [13, 17]. These data are usually referred to malignant neoplasms of vulva or genital tract. Copeland et al. [6] in large cohort of 700 patients with vulvar carcinoma diagnosed 52 cases of Bartholin's gland cancer (7%). In our study based on Bartholin's gland pathologies only, all neoplasms constitute 3% and malignant 2%. Interestingly, all tumors occurred in female patients with a rare blood type, what was not matter of interest in the literature up to the present. The majority of Bartholin's gland carcinomas is of squamous cell type [4, 6, 13]. In study of Blat et al. [1] squamous cell carcinomas constituted 67% of malignancies. In our study group represented 100% of carcinomas but small number of cases makes impossible for us to estimate its frequency validly. Leuchter et al. [13] after review of the literature and collection 90 cases of Bartholin's gland carcinoma demonstrated that only 7,8% of patients were treated for infection or inflammatory changes of the gland in issue. Thus there is no evidence that inflammatory processes within Bartholin's gland are associated with carcinogenesis. In our material any of three neoplasms did not present inflammatory infiltration. Wide histological variability of Bartholin's gland's ductal and glandular epithelium in our patients were observed more often in non-inflammatory than inflammatory cysts. These observations suggest need for analysis of epithelial changes on molecular level (Ki-67, other cell cycle proteins) which could explain pathways of carcinogenesis in Bartholin's gland.

Pathogenesis of endometriosis in Bartholin's gland described for the first time by Matseoane et al. [14] is also unsolved. Three potential explanation regarding the origin of these dispersed lesions, namely the regurgitation, metaplastic and vascular or lymphatic dissemination theory are widely known. In our study group endometriosis was diagnosed in almost 2% of cases and was in 100% localized on the left side, identically to data reported by Matseoane et al. [14], but conversely to that establish by Gocmen et al. [9] on the right side in the latest report. Fibroleiomyoma was referring to case report in our material and corresponded to observations of authors from Israel [18]. In clinical examination 50% of Bartholin's gland neoplasms was misdiagnosed as cyst or abscess [5]. Three cases from our group were diagnosed just as "tumor". This term many a time referred to cysts and abscesses and so in this study we took no account of agreement between clinical and histopathological diagnosis. Critical problem connected with the proper patients' management was delay in establishing of final histopathological diagnosis what was incident of very frequent occurrence [6]. Mean time of delay in final diagnosis was 10,8 months [13], but in the case of Czorniuk and Stopińska [8] was even eleven years and that is why female patients with Bartholin's gland cysts without response to conventional therapy should undergo diagnostic biopsy or exploratory cystectomy.

Acknowledgment: We would like to thank Prof. dr hab. J. Rabczyński for making microphotographs.

References

1. Balat O, Edwards CL, Delclos L: Advanced primary carcinoma of the Bartholin's gland: report of 18 patients. *Eur J Gynec Oncol* 2001, 22, 46–49.
2. Bergan T: Anaerobic bacteria as cause of infections in female genital organs. *Scand J Gastroenterol Suppl* 1983, 85, 37–47.
3. Brook I: Aerobic and anaerobic microbiology of Bartholin's abscess. *Surg Gynaec Obstet*, 1989, 169, 32–34.
4. Cardosi RJ, Speights A, Fiorica JV, Grendys EC Jr, Hakam A, Hoffman MS: Bartholin's gland carcinoma: A 15-year experience. *Gynec Oncol* 2001, 82, 247–251.
5. Chamlian DL, Taylor F, Taylor HB: Primary carcinoma of Bartholin's gland. A report of 24 patients. *Obst Gynecol* 1972, 39, 489–494.
6. Copeland LJ, Sneige N, Gershenson DM, McGuffee VB, Abdul-Karim F, Rutledge FN: Bartholin gland carcinoma. *Obstet Gynecol* 1986, 67, 794–801.
7. Czastikowa AW, Kuncewicz LD, Starostina ZD, Owsianikowa RD, Struganckaja GS: Klinika i diagnostika gonorejnych bartolinitiw. *Akush. Ginekol. (Moskova)*, 1977, 12, 54–55.
8. Czorniuk A, Stopińska U: Szczególna postać pierwotnego raka gruczołu Bartholina. *Pat Pol* 1975, 26, 293–297.
9. Gocmen A, Inaloz HS, Sari I, Inaloz SS: Endometriosis in the Bartholin's gland. Case report. *Europ J Obstet Gynecol Reprod Biol* 2004, 114, 110–111.
10. Klasa-Mazurkiewicz D, Emerich J, Milczek T, Ciach K: Pierwotny rak gruczołu Bartholina. *Gin Pol* 2003, 74, 220–223.

11. *Krasevic M, Haller H, Internicka Z, Valstelic I, Matejic N*: Adenoid cystic carcinoma of Bartholin's gland: A case report. *Europ J Gynec Oncol* 2001, 22, 213–214.
12. *Lauffer B, Beckmann MW, Bender H G, Buslau U*: Aktuelle Diagnostik und Therapie entzündlicher Vulvaerkrankungen. *Gynekologe* 1993, 26, 247–256.
13. *Leuchter RS, Hacker NF, Voet RL, Berek JS, Townsend DE, Lagasse LD*: Primary carcinoma of the Bartholin gland: A report of 14 cases and review of the literature. *Obstet Gynecol* 1982, 60, 361–368.
14. *Matseoane S, Harris T, Moscovitz E*: Isolated endometriosis in a Bartholin gland. *N.Y. State J Med* 1987, 87, 575–576.
15. *Mayer HO, Burmucic R*: Anaerobe Keime im gynakologischen Untersuchungsmaterial. Häufigkeit und klinische Bedeutung. *Zantrbl Gynakol*, 1987, 109, 1118–1125.
16. *Morton III B D, McCarthy L R*: Bartholinitis – an unusual etiologic agent. *Obst Gynecol* 1980, 3 (Suppl), 97S–98S.
17. *Nasu K, Kawano Y, Takai N, Kashima K, Miyakawa I*: Adenoid cystic carcinoma of Bartholin's gland. *Gynecol Obst Invest* 2005, 59, 54–58.
18. *Neri A, Peled Y, Braslavski D*: Vulvar leiomyoma. *Acta Obstet Gynecol Scand* 1993, 72, 221–222.
19. *Peters III WA*: Bartholinitis after vulvovaginal surgery. *Am J Obstet Gynecol* 1998, 178, 1143–1144.
20. *Sing A, Roggenkamp A, Kress K, Autenrieth IB, Heesemann J*: Bartholinitis due to *Streptococcus pneumoniae*: Case report and review. *Clin Infect Dis*, 1998, 27, 1324–1325.
21. *Sweet RL, Schachter J, Landers DV*: Chlamydial infections in obstetrics and gynecology. *Clin Obstet Gynecol* 1983, 26, 143–164.

Address for correspondence and reprint requests to:

Henryk Sośnik
Jaracza 82B/4
50–305 Wrocław
Tel: +48 071 791 41 29
E-mail: ahalon@anpat.am.wroc.pl