

Sami Titi¹, Kinga Sycz¹, Marek Umiński²

Primary Fibrosarcoma of the Thyroid Gland-a Case Report

¹Department of Pathomorphology,

²Surgeon Ward, Independent Public Provincial Hospital Complex, Szczecin

A 54-year-old woman, a teacher with a two-year history of a thyroid gland enlargement was referred to the Surgeon Ward with a preliminary cytological diagnosis of schwannoma. Histological examination of the resected tumour revealed a malignant mesenchymal tumor and a primary fibrosarcoma of the thyroid gland was ultimately confirmed. Currently, a follow-up, with further clinical investigations has been recommended.

Introduction

Fibrosarcoma is a malignant mesenchymal neoplasm of the fibrous soft tissue making up 1–3% of human sarcomas. Primary fibrosarcoma occurring in the thyroid is exceptionally rare. Deep soft tissues of the lower extremities, particularly thigh and knee are the most frequently involved sites [4, 10]. It also may occur in the upper extremities, trunk, head, neck and rarely in breast, lungs and central nervous system. Fibrosarcomas occur both in adults and in children but most often at 30–55 years. They mainly grow *de novo*, but can also arise in a postsclerotic cicatrix, site of previous trauma, post-radiotherapy and as a result of exposition to asbestos or other chemical materials [4, 6, 3].

We did not find any publications about this type of thyroid tumour in Polish literature, thus we think this case is worth reporting.

A Case Description

The patient was a 54-year-old woman, a teacher who was complaining of a gradual enlargement of the thyroid gland over the last two years and considerable increase in size of the right lobe within the last several months. A familial history of nodular goiter was found. Ultrasonography investigation of the thyroid revealed the presence of a lesion with a heterogenous echostructure of 6.1 cm in diameter.

The tumour involved the whole right lobe and was surrounded by vessels modulation. The left lobe showed 4 isoechoic lesions 0,7 to 0,9 cm in diameter. The neighbouring lymph nodes were of normal size.

The cytodiagnosis (No 7245/2004) of a schwannoma in the right lobe was suggested as a result of the fine needle aspiration (FNA), which was conducted in a Non-public Diagnostic Department in Szczecin. FNA of the left lobe revealed several little groups of follicle cells with no cytological features of malignancy. The results of remaining examinations were within the limit of norm. The patient was admitted to the Surgeon Ward of the Independent Public Provincial Hospital Complex in Szczecin (IPPHC). On admission she was euthyroid, but complained of dysphagia, insomnia, headache and rachialgias. The physical examination showed a firm, fixed, solitary and big mass in the right lobe of the thyroid but without skin changing over the lesion. On December 13, 2004 a total thyroidectomy with a selective lymphadenectomy was performed.

On sectioning, a solitary, well circumscribed, lobulated and grey-white tumour, measuring maximum 6 cm in dimension was identified in the right lobe. The tumour appears to replace almost the entire cut surface of the thyroid lobe (Fig. 1).

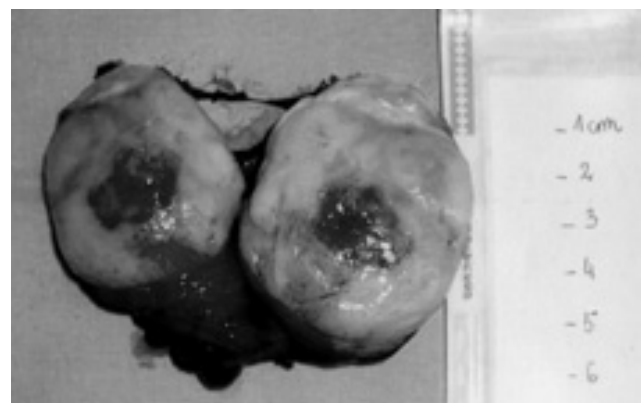


Fig. 1. Surgical specimen. Lobulated grey-white tumour involving the whole lobe of the thyroid gland.

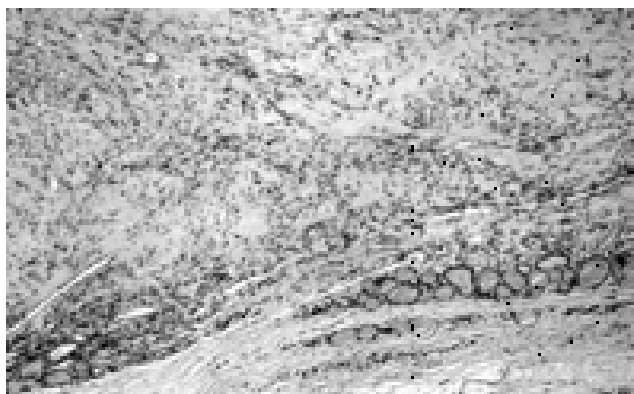


Fig. 2. Thyroid tissue showing atrophic changes due to the pressure of fibrosarcoma. HE. Magn. 25 \times .

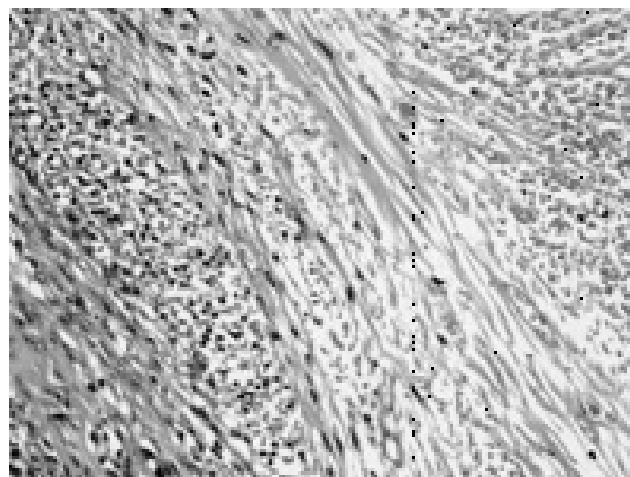


Fig. 5. Fibrosarcoma showing diffuse necrosis. HE. Magn. 200 \times .

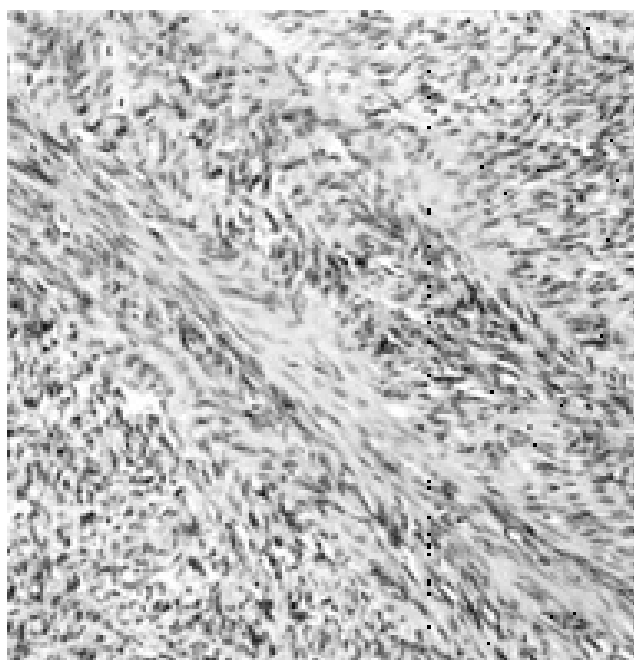


Fig. 3. Fibrosarcoma composed of malignant spindle cells arranged in a herringbone pattern. HE. Magn. 100 \times .

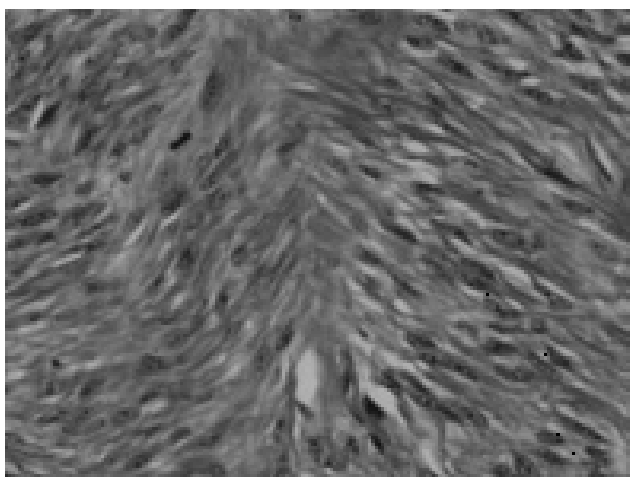


Fig. 6. The background of fibrosarcoma with abundant collagen fibers stain red. Von Gieson stain. Magn. 200 \times .

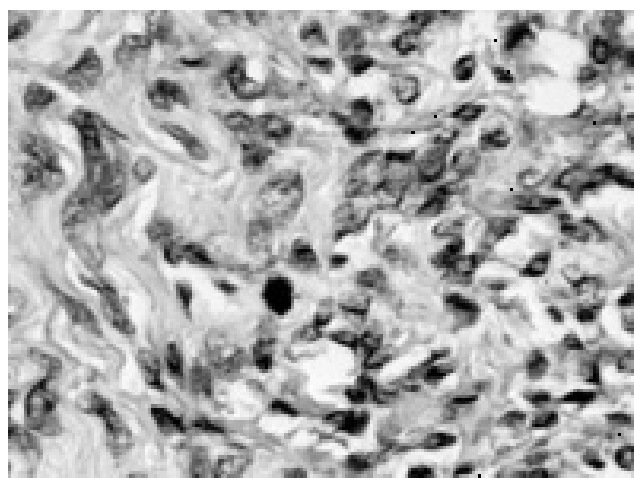


Fig. 4. Fibrosarcoma with a mitotic figure. HE. Magn. 400 \times .

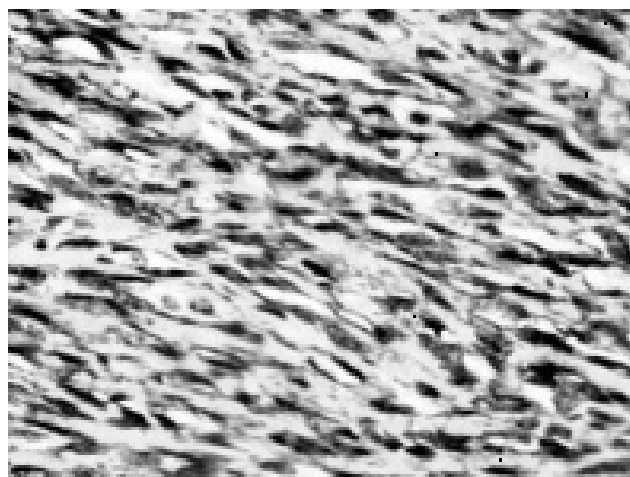


Fig. 7. Fibrosarcoma. Spindle cells exhibit positive reaction for vimentin. Imm. Magn. 200 \times .

The histological examination (No A.21150–60/2004) of the tumour revealed morphological features of malignant spindle cells arranged in fascicles with herringbone patterns producing collagen fibers in the background (Fig. 3, 6). Mitotic figures and foci of necrosis were observed (Fig. 4–5). The peripheral thyroid parenchyma showed atrophic changes due to the tumour pressure (Fig. 2). The surgical excision margins were free from neoplastic infiltration. Immunohistochemical reactions were performed and the tumour cells showed strong positive reaction for vimentin (Fig. 7). However, negative reactions were observed for cytokeratin, S-100 and desmin. In the left lobe there were features of nodular hyperplasia and chronic inflammation. Twelve cervical lymph nodes showed only reactive changes. Radiotherapy was applied as a supplementary treatment, and the patient was treated with Letrox, due to the post-operative hypothyreosis. A checkup with X-ray film of the chest disclosed no changes. In 2006, liver CT examination revealed 2 small hypodense lesions; the first one 0,4 cm in diameter and looking like a cyst, the second 0,5 cm in diameter with ambiguous radiological appearance. In March 2006, the Commission of Hepatic Diseases and Transplantations (CHDT) in the IPPHC decided to keep the patient under a supervision and recommended CT control examination of the chest and liver after several months.

Discussion

The presented case of a primary fibrosarcoma of the thyroid gland is unusual and noteworthy, since several isolated cases were reported [1, 2, 5, 7]. This tumour hasn't been yet included in the most recent TNM classification of thyroid tumours [3]. Clinical symptoms and radiological signs are not characteristic. It is worth mentioning that in our case the 2-year tumour history is a relatively rapid course of neoplasm, which is generally known as a slow-growing tumour. The patient was clinically euthyroid despite the atrophic changes caused by lesion mass pressure. In the pre-operative differential diagnosis the neoplasm presented considerable problems. FNA failed to make the correct diagnosis and schwannoma was suspected. In spite of the initial diagnosis of benign mesenchymal tumour, fortunately total thyroidectomy with adequate margins was conducted by a surgeon with a great care, without the need of intraoperative histological examination.

The survival rate in fibrosarcoma is closely related to the histological grade indicated by several morphological features, such as tumour cellularity, cellular polymorphism, mitotic activity and necrosis [8, 10]. The histological examination of the lesion revealed medium cellular density with a slight polymorphism, abundant intervening collagen fibers,

6 mitoses per 10 high power fields and foci of necrosis. These features allowed to classify this tumour as a well differentiated fibrosarcoma, which is correlated with a long term survival rate. The metastases rate fluctuates between 34% to 63% over 1–5 years and correlates well with the tumour histological grade [9]. They occur mostly by the way of blood stream, mainly in lungs and skeleton [10], thus the removal of regional lymph nodes is usually not necessary. According to CHDT decision, the patient remains under supervision, since the liver lesions disclosed by CT examination should be verified. Local recurrence is often associated with the status of the surgical margins [9]. Rich cellular tumours showing more than two mitoses per high power field, containing little collagen fibers, foci of necrosis and with inadequate tumour excision seem to have the worst prognosis. The patient age is also an important prognostic factor. Better prognosis was observed in children under 10 years of age [8, 10].

The appearance of spindle cells with slight polymorphism arranged in fascicles with significant histological features such as herringbone pattern, the presence of intervening collagen fibers and foci of necrosis made the correct pathological diagnosis in our case relatively easy. However, in differential diagnosis of well differentiated fibrosarcoma, we had to take into account benign lesions such as nodular fasciitis and fibromatosis as well as malignant tumours for example malignant spindle cell carcinoma, monophasic fibrous synovial sarcoma, malignant peripheral nerve sheath tumour (MPNST), desmoplastic leiomyosarcoma and malignant fibrous histiocytoma (MFH) [10]. Nodular fasciitis is a smaller lesion, it grows rapidly and microscopically shows short bundles and sweeping fascicles with scattered mononuclear inflammatory cells. Fibromatosis has more collagen fibers, less cellular, less mitoses and with no necrosis or nuclear overlap or hyperchromasia. Negative immunohistochemical reaction for cytokeratin in neoplastic cells allowed to rule out spindle cell carcinoma and monophasic fibrous synovial sarcoma. MPNST and leiomyosarcoma were also excluded, because of the negative expression for S-100 and desmin respectively. In small number of fibrosarcomas there is positivity for neural markers including S-100 and NSE (neuron-specific enolase), making differentiation from MPNST more difficult. The cells in MPNST have irregular fascicular growth pattern with perivascular cuffing and may form whorls or palisades. Moreover there is often transition between malignant and benign neurofibroma-like areas. MFH occurs in elderly patients and histologically is characterized by storiform pattern and the presence of multinucleated bizarre giant cells, siderophages and xanthoma cells. There is unusual variant of fibrosarcoma called sclerosing epithelioid type, which is characterized by abundant collagen fibers surrounding small cells with clear cytoplasm. The

expression of EMA (epithelial membrane antigen) is positive in up to half of these tumours and thus the identification of conventional foci of fibrosarcoma allows to discern these tumours from infiltrating lobular carcinoma or signet ring adenocarcinoma. Negative staining for LCA and HMB-45 is helpful in differential diagnosis with sclerosing lymphoma and clear cell sarcoma respectively [10].

Fibrosarcoma should be treated surgically with adequate margins and a supplementary radiotherapy should be applied if inadequate margins cannot be obtained. An adjuvant chemotherapy is applied in patients with high grade fibrosarcomas [10].

References

1. *Agarwal PK, Wahal KM, Mehrota RM*: Fibrosarcoma of the thyroid. *Indian J Cancer* 1976, 13, 375–378.
2. *Botman T*: Fibrosarcoma of the thyroid gland. *Ned Tijdschr Geneesk* 1958, 4, 47–49.
3. *Ellellis RA, Williams ED*: Thyroid and parathyroid tumours. In: *Tumours of endocrine organs*. Ed. Delellis A, Lloyd RV, Heitz PU, Eng C. IARC Press Lyon 2004, 51.
4. *Fisher C, Van den Berg E, Molenaar WM*: Adult fibrosarcoma. In: *Tumours of Soft Tissue and Bone*. Ed. Fletcher DM, Unni KK, Mertens F. IARC Press Lyon 2002, 100–101.
5. *Fries JG, Chamberlin LA, Vandivier TG*: Primary fibrosarcoma of the thyroid. Case report. *Tex State J Med* 1961, 57, 981–982.
6. *Niezabitowski A, Szczepański W, Stachura J*: Choroby kości, stawów, nowotwory tkanek miękkich. In: *Stachura J, Domagała W. Patologia, znaczy słowo o chorobie, tom II, patologia narządowa część 2*, PAU, Kraków, 2005, 1149–1200.
7. *Rilke F, Tommasini DA*: Fibrosarcoma of the thyroid gland. Report of two cases. *Folia Endocrinol Mens Incretologia. Incretoterapia* 1958, 11, 527–542.
8. *Rosai J*: *Ackerman's Surg Path* Ed 9. St Louis, Toronto 2004, 2252–2254.
9. *Scott SM, Reiman HM, Pritchard DJ et al*: Soft tissue fibrosarcoma: a clinicopathological study of 132 cases. *Cancer* 1989, 64, 925.
10. *Weiss SW, Goldman JR*: Fibrosarcoma. In: *Soft Tissue Tumors*. 4th Ed. Weiss SW, Goldman JR. Mosby. St Louis, London, Philadelphia, Sydney, Toronto 2001, 409–436.

Address for correspondence and reprint requests to:

Sami Titi M.D, Ph.D.
 Consultant Histopathologist
 Pathology Department
 The Royal Oldham Hospital
 Rochdale Road
 Oldham, OL 1 2JH
 Email: sami.titi@pat.nhs.uk