

Marian Danilewicz, Małgorzata Wągrowaska-Danilewicz

A Morphometric Insight into Glomerular and Interstitial Lesions in Acutely Rejected Renal Allografts*

Department of Nephropathology, Medical University of Łódź

Twenty-four renal allograft biopsy specimens from patients with acute renal transplant rejection (ARTR) for whom both light and electron microscopy as well as immunofluorescence microscopy and full clinical data were available were examined quantitatively. The specimens had similar histologic Banff 97 (IA and IB) scores. As a control 10 biopsy specimens of the kidneys removed because of trauma were used. Morphometric investigations were performed by means of a computer image analysis system to evaluate glomerular and interstitial lesions in ARTR. Another purpose of our study was to ascertain the possible relationships between α -smooth muscle actin (α -SMA) expression and selected morphometric parameters as well as monocyte/macrophage count. Our study revealed that the mean values of total glomerular cells per total glomerular area, mesangium (% of total glomerular area), glomerular and interstitial α -SMA staining, glomerular and interstitial monocytes/macrophages as well as interstitial volume were increased in ARTR in comparison with controls. In ARTR group significant positive correlations existed between glomerular expression of α -SMA and total glomerular cells per total glomerular area, as well as glomerular CD68+ cells. Moreover, interstitial expression of α -SMA and interstitial volume, as well as interstitial CD 68+ cells were in ARTR patients also positively and significantly correlated. Similarly, in this group positive significant correlation between interstitial volume and interstitial CD 68+ cells was noted. In conclusion, our study suggests that glomerular hypercellularity and mesangial changes are common in ARTR, whereas enhanced interstitial fibrosis confirms a risk of early allograft injury in these cases.

Introduction

The routine success of renal transplantation today is the culmination of worldwide basic and clinical research that spans almost a century [10]. Today renal transplantation has proved to be a cost-effective therapy for end-stage renal failure, which improves the quality of life for recipients [7]. However, despite major advances in immunosuppression

and transplant management acute and chronic rejections are still the major causes of renal allograft loss [18]. Acute rejection has been shown to be strongest predictive factor of subsequent chronic rejection [9]. Acute renal transplant rejection (ARTR) is characterized by intimal endothelialitis/arteritis and tubulitis [14]. Immunohistochemically, strong expression of ICAM-1, vascular cellular adhesion molecule-1 and MHC class II antigens on tubular and endothelial cells along with interleukin-2 receptor bearing infiltrates of T-lymphocytes and significant presence of macrophages were highly correlated with ARTR [4]. Recently early interstitial fibrosis in cadaveric renal allografts is stressed [1]. Moreover, significant increase in interstitial myofibroblasts in the first postengraftment biopsy specimens was suggested to be a prognostic factor in ARTR [19]. Although in about half of biopsies of ARTR glomerular lesions are noted [16], to our knowledge no data have documented these changes quantitatively.

Therefore, in this paper we report the quantitative characteristics of glomerular and interstitial lesions in ARTR. Another purpose of our study was to ascertain the possible relationships between α -smooth muscle actin (α -SMA) expression and selected morphometric parameters as well as monocyte/macrophage count.

Material and Methods

Patients

Twenty-four renal allograft biopsy specimens from patients with ARTR were examined by percutaneous renal biopsy. All biopsies had been performed solely for diagnostic purposes. All our patients were adults: the mean age was 46.1 ± 11.1 and the male to female ratio was 14:10. The specimens were taken from 7 days to 4 months after engraftment (mean 35.5 days). Morphological diagnosis of ARTR was established independently by two experienced nephro-

*This work was supported by Medical University in Łódź, grant no 502-11-715(70)

pathologists according to Banff 97 criteria [20] and based on light microscopy, immunofluorescence and electron microscopy. The specimens had similar histologic Banff 97 (IA and IB) scores. The standard immunosuppression protocol was used in all patients. As a control 10 biopsy specimens of the kidneys removed because of trauma were used (the male to female ratio was 7:3, the mean age was 38.1 ± 7.2). None of the persons from whom renal tissue originated were known to have had previous or actual renal disease. Before the quantitative examination was carried out, all control specimens were histologically examined by a nephropathologist and found to be normal renal tissue.

Light microscopy

Tissue specimens were embedded in paraffin, sections cut precisely at $4\mu\text{m}$, and stained by hematoxylin and eosin, periodic acid-Schiff (paS)-alcian blue, trichrome light green (Masson), and by silver impregnation (Jones). Thickness of each section was controlled according to the method described by Weibel [24].

Immunofluorescence microscopy

Tissue was snap frozen, sectioned at $5\mu\text{m}$ and fixed in 95% alcohol for 10min. Sections incubated with FITC-antisera (Hoechst) to human IgG, IgA, IgM and complement (C3) were viewed on Olympus BX41 microscope, using proper filters.

Electron microscopy

Tissue was fixed in glutaraldehyde, post-fixed in 1% osmium tetroxide, embedded in epon and sectioned on a LKB ultratome. Sections were stained by lead citrate and uranyl acetate, and viewed in a JEM 100B electron microscope.

Immunohistochemistry

The preparation and staining of tissue sections for immunohistochemistry (an indirect StreptABComplex/HRP technique) was carried out as follows: paraffin-embedded tissues, after deparaffinization and rehydration were reacted for 5 minutes with 3% hydrogen peroxide in distilled water. If necessary, pre-treatment with Trypsin (DAKO) for 15 minutes at 37°C was performed (monoclonal antibody anti-CD68). After blocking by normal rabbit serum (DAKO) during 20 minutes (dilution 1:5), the sections were incubated with the following solutions, each followed by TBS washing: appropriately diluted mouse antihuman monoclonal antibodies (in a moist chamber for 30 minutes at room temperature), biotinylated rabbit anti-mouse immunoglobulin (DAKO) diluted 1:600 in TBS for 20 minutes, and StreptABComplex/HRP (DAKO) for 30 minutes prepared according to the instruction. The final reaction was achieved

TABLE 1

Monoclonal antibodies employed and their specificity

Monoclonal antibody	Specificity	Source	Dilution
α -SMA	Myofibroblasts, smooth muscles	Dako	1:50
CD68+	Monocytes / macrophages	Dako	1:100

by incubating the sections with 3.3'-diaminobenzidine (DAB tablets DAKO) 0.5mg/ml Tris-HCL buffer, pH 7.6, containing 0.02% hydrogen peroxide, for 10 minutes. After washing, sections were counter-stained with hematoxylin and coverslipped.

The monoclonal antibodies (DAKO) employed, their specific reactivities and dilutions are listed in Table 1.

Tissue control for immunostaining

For each MoAb and for each sample a positive control was processed (for monocytes/macrophages paraffin-embedded sections of surgically removed lymph node and vascular smooth muscle cells of the renal biopsy specimens for myofibroblasts). Moreover, the following negative controls were used: 1) omission of primary antibody, 2) incubation with appropriately diluted mouse IgG (DAKO) as a first layer. The samples were prepared by the same method as described above. Specificity of labeling was shown by lack of staining in these samples.

Morphometry

Histological morphometry was performed by means of image analysis system consisting of a IBM-compatible computer equipped with an optical mouse, Indeo Fast card (frame grabber, true-color, real-time), produced by Indeo (Taiwan), and color TV camera Panasonic (Japan) linked to a Carl Zeiss Jenaval microscope (Germany). This system was programmed (program MultiScan 8.08, produced by Computer Scanning Systems, Poland) to calculate:

- the surface area of a structure whose perimeter was traced;
- the number of objects (automatic function with manual correction or semiautomatic function);
- the surface area of a structure using stereological net (with regulated number of points).

The colored microscopic images were saved serially in the memory of the computer, and then quantitative examinations had been carried out. The quantitative examination included the following parameters:

- total glomerular area (the inner limit of Bowman's capsule was traced out using a cursor of an optical mouse and used in further calculations);

TABLE 2

A morphometric comparison of glomeruli and renal interstitial tissue in cases with ARTR and controls

	Controls (n=10)	ARTR (n=24)	P value
Total glomerular area (μ^2)	21829.3 \pm 3425.6	22345.7 \pm 3675.2	=0.7 (NS)
Total glomerular cells per total glomerular area	100.2 \pm 13.3	118.4 \pm 16.1	<0.01
Mesangium (% of total glomerular area)	8.6 \pm 0.8	9.7 \pm 1.4	<0.03
Glomerular α -SMA staining (% of total glomerular area)	0.19 \pm 0.11	0.42 \pm 0.27	<0.02
CD68+ cells/glomerular cross-section	1.0 \pm 0.7	1.98 \pm 1.1	<0.02
Interstitial volume (%)	10.08 \pm 1.25	18.72 \pm 6.43	<0.001
Interstitial α -SMA staining (%)	0.52 \pm 0.26	8.17 \pm 6.27	<0.001
Interstitial CD68+ cells/mm ²	33.96 \pm 17.91	158.25 \pm 96.21	<0.001

Data are expressed as mean \pm standard deviation

- total glomerular nuclei per total glomerular area: mesangial, endothelial, visceral epithelial nuclei and leukocytes (these objects were automatically counted in hematoxylin and eosin stained sections and followed out with manual correction, as needed). The number of CD68 positive cells per glomerular cross-section in each section was also obtained (semiautomatic function) and used in the analysis. Extracapillary cells, such as in crescents, where present, were excluded from the count of intraglomerular immune cells.
- α -SMA staining per cent of total glomerular area and mesangial area per cent of total glomerular area (in paS-alcian blue staining). These parameters were measured using point counting method which is an adaptation of the principles of Weibel [24]. The point spacing being 16 μ m. Total number of the points of a net was 169, and total area was 36864sq. μ m. The percentage of α -SMA staining and mesangial area was an expression of the number of points overlying these structures as a percentage of the total points counted.
- interstitial myofibroblasts were identified by their morphology and positive staining with anti- α -SMA. The interstitial immunoperoxidase staining for α -SMA was also measured using point counting method. Under the net described above, 8 - 10 randomly selected adjacent fields of the renal cortex were investigated. Glomeruli and large blood vessels were neglected. The percentage of α -SMA positive staining was an expression of the number of points overlying α -SMA positive areas as a percentage of the total points counted.

The same method was used to estimate interstitial volume (including edematous changes) in sections stained with Masson trichrome. The percent interstitial volume was an expression of the number of points overlying renal cortical interstitium as a percentage of the total points counted.

The interstitial infiltration of monocytes/macrophages was determined by counting all positive cells (semiautomatic function) in a sequence of ten consecutive computer images of 400x high power fields - 0.0047mm² each. Only immunoreactive cells with the clear identifiable nucleus were counted. The only adjustments of field were made to avoid glomeruli and large vessels. The results were expressed as a mean number of immunopositive cells per mm².

Statistical methods

Differences between groups were tested using unpaired Student's t-test preceded by evaluation of normality and Levene's test. The Mann-Whitney U test was used where appropriate. Correlation coefficients were calculated using Spearman's method. Results were considered statistically significant if p<0.05.

Results

The morphometric data of the glomerular and interstitial parameters appear from Table 2.

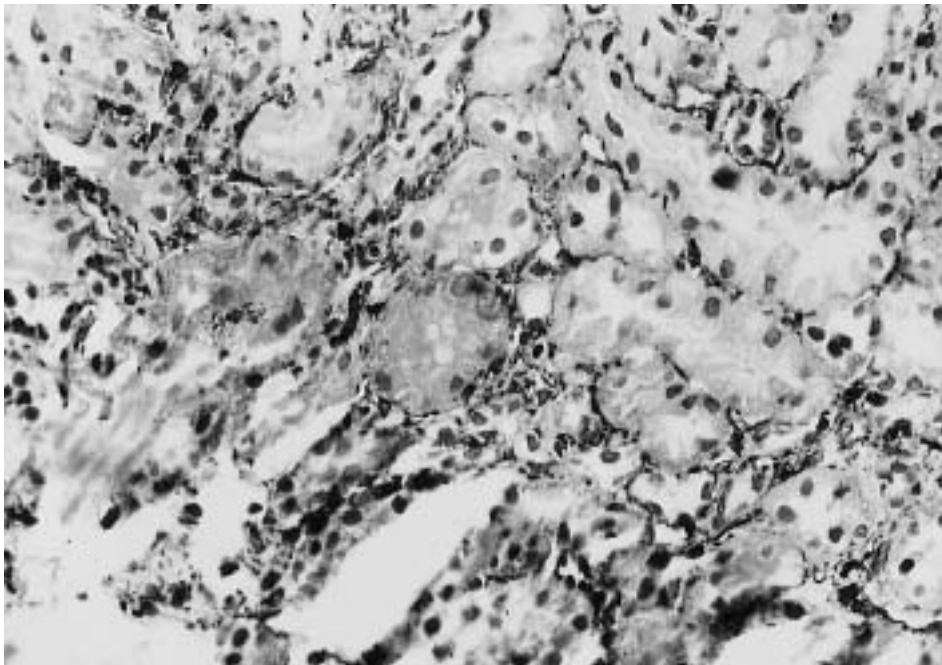
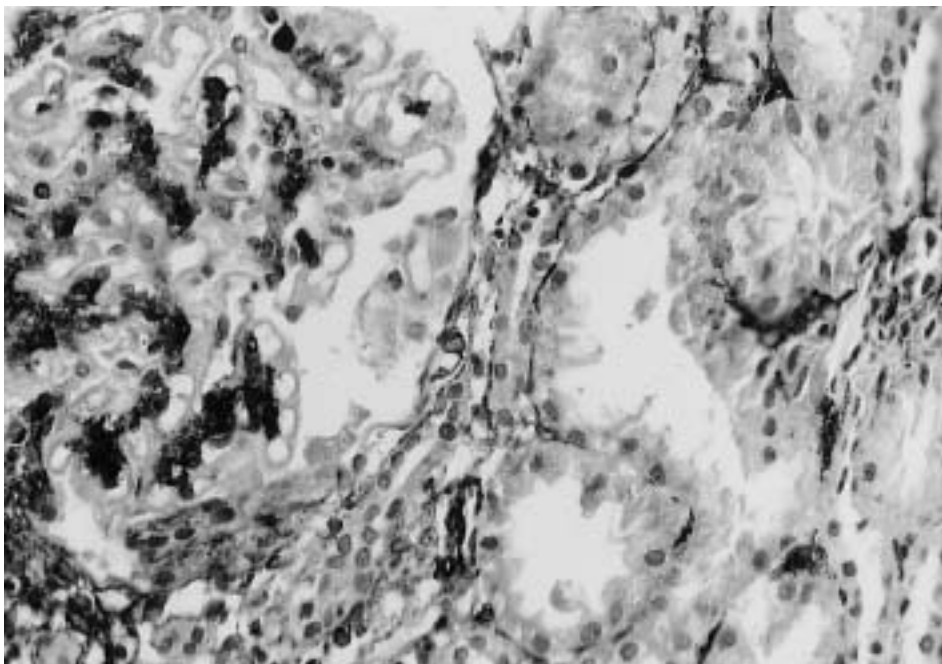
The mean values of total glomerular cells per total glomerular area, mesangium (% of total glomerular area), glomerular and interstitial α -SMA staining (Figs. 1 - 2), glomerular and interstitial monocytes/macrophages (Figs. 3 - 4) as well as interstitial volume were in ARTR increased in comparison with normal controls. The mean values of total glomerular area were similar in ARTR and controls.

The correlations between selected glomerular and interstitial parameters in patients with ARTR and controls are shown in Table 3. In ARTR group significant positive correlations existed between glomerular expression of α -SMA and total glomerular cells per total glomerular area, as well as glomerular CD68+ cells. Moreover, interstitial expression of α -SMA and interstitial volume, as well as interstitial CD68+ cells were in ARTR patients also positively and significantly correlated. Similarly, in this group positive

TABLE 3

Spearman's rank order correlations between selected glomerular and interstitial parameters in patients with ARTR and controls

Pair of variables	Controls (n=10)	ARTR (n=24)
α -SMA staining (% of total glomerular area) and total glomerular cells per total glomerular area	r=0.12, p-NS	r=0.56, p<0.005
α -SMA staining (% of total glomerular area) and mesangium (% of total glomerular area)	r=0.09, p-NS	r=0.14, p-NS
α -SMA staining (% of total glomerular area) and CD68+ cells/glomerular cross-section	r=0.21, p-NS	r=0.62, p<0.002
interstitial expression of α -SMA and interstitial volume	r=0.52, p=0.1(NS)	r=0.72, p<0.001
interstitial expression of α -SMA and CD68+ cells	r=0.22, p=0.4(NS)	r=0.59, p<0.003
interstitial volume and CD68+ cells	r=0.18, p=0.6(NS)	r=0.48, p<0.02

Fig. 1. Weak peritubular immunoperoxidase staining for α -SMA in control patient. Magn. 400x.Fig. 2. Strong glomerular and interstitial immunoperoxidase staining for α -SMA in patient with ARTR. Magn. 400x.

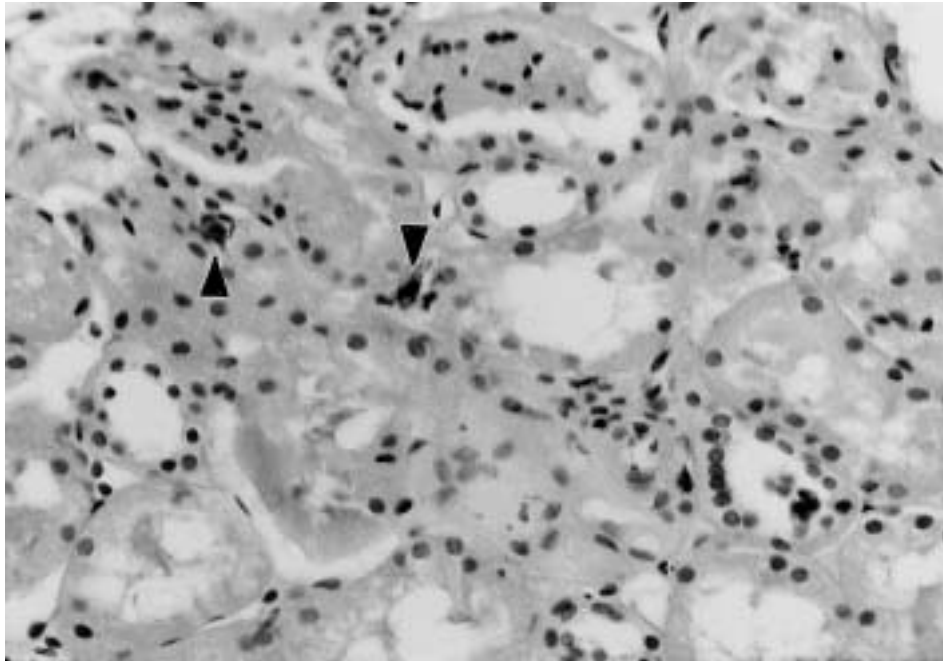


Fig. 3. In controls only few interstitial CD68+ cells can be seen (arrows). Magn. 400x.

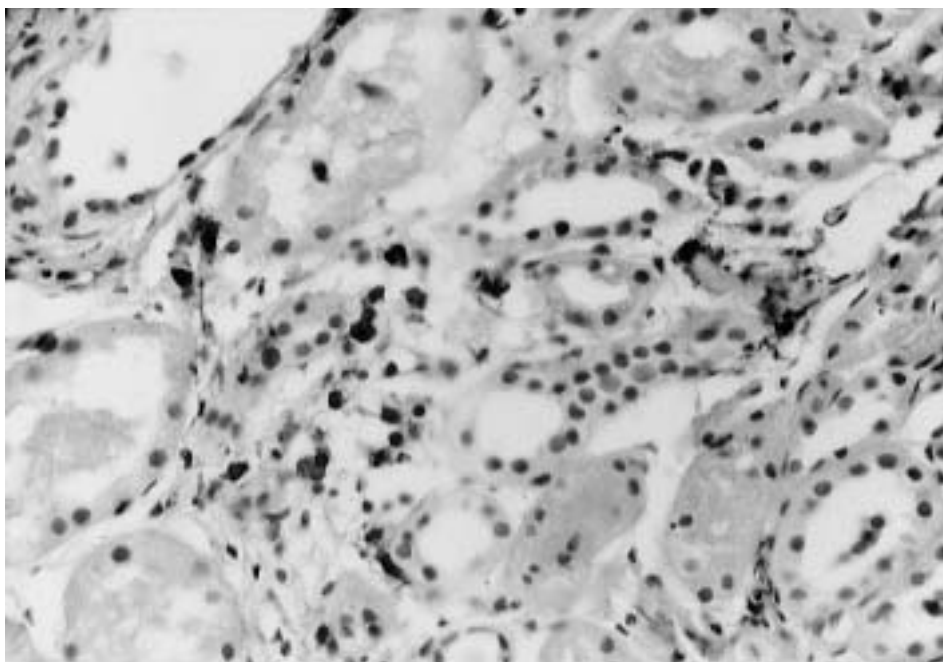


Fig. 4. Prominent interstitial infiltrates of CD68+ cells in patient with ARTR. Magn. 400x.

significant correlation was noted between interstitial volume and interstitial CD68+ cells. The correlation between glomerular expression of α -SMA and glomerular mesangium and all correlations in control group were weak and not significant.

Discussion

Glomerular abnormalities in ARTR are well known and vary from minor infiltrates of mononuclear cells and focal reactive changes of the endothelial cells termed glomerulitis, to severe acute allograft glomerulopathy where most of

glomeruli show hypercellularity, injury and enlargement of endothelial cells, infiltration of glomeruli by mononuclear cells, and webs of paS-positive material [5, 10, 13]. However, as was mentioned in introduction, no available data documented quantitatively glomerular lesions in ARTR. The present study showed that the mean values of total glomerular area did not differ significantly in ARTR and controls. Similarly Bathena [8] found glomerular enlargement only in allografts with focal glomerulosclerosis detected in graft recipients 3 years after transplantation. On the other hand, we revealed that the mean values of total glomerular cells per total glomerular area and mesangium (% of total glome-

ular area) were in ARTR significantly increased in comparison with controls. As we were aware, that glomerular hypercellularity in ARTR not only depended on mesangial proliferation but also on endocapillary accumulation of mononuclear cells, quantitative evaluation of glomerular CD68+ cells was performed. As might be expected, glomerular monocytes/macrophages were in ARTR significantly more numerous in comparison with control group. However, the prognostic significance of these morphometric findings remains controversial. The results of Axelsen et al. [5] suggested that endocapillary hypercellularity indicates a poor graft survival whereas data of Olsen et al. [16] did not demonstrate any adverse effects of endocapillary hypercellularity on graft function or graft prognosis. Similarly, Messias et al. [13] found that this glomerular lesion was not an independent predictor of graft survival. The role of glomerular macrophage infiltration in renal allografts is suggested in the recent paper of Ozdemir et al. [17]. These authors concluded that presence of glomerular macrophages can be considered a marker for rejection and indicated that the outcome of the graft will be significantly worse than the grafts without intraglomerular macrophage infiltration. Moreover we found in ARTR a significant increase of glomerular α -SMA expression as compared with controls. To our knowledge no available data documented quantitatively glomerular expression of α -SMA in ARTR. In the present study normal glomeruli showed only few α -SMA positive cells whereas in ARTR group mesangial α -SMA positive cells were observed with a segmental distribution. Similarly, Alpers et al. [3] found that α -SMA was still frequently present in the mesangium of histologically normal kidneys obtained from patients without known renal disease other than localized tumors and demonstrated, that enhanced α -SMA expression can usually be detected in the mesangium in any form of glomerular injury. Although our results of glomerular α -SMA expression suggest glomerular injury in ARTR the analysis of the correlations between morphometric glomerular parameters and glomerular expression of α -SMA has provided some interesting insights into the nature of the local mechanisms leading to phenotypic changes of the mesangial cells. A major finding in this study was the demonstration that in ARTR was significant positive correlation between glomerular expression of α -SMA and total glomerular cells. Therefore, our observations are consistent with prior suggestions, that α -SMA synthesis in mesangial cells is frequently associated with increased cell proliferation and mesangial matrix production [3]. These phenotypic changes may be an indicator of mesangial cells activation after injury and may have important pathophysiologic consequences [12].

Interestingly, significant positive correlations existed in ARTR between glomerular α -SMA staining and glomerular CD68+ cells. This observation raises the possibility that

monocytes/macrophages play a role in phenotypic changes of the mesangial cells, however, we are aware that a morphometric analysis does not lend itself to establish such casual associations.

As regard renal interstitial volume, the recent papers of El Nahas group surprisingly suggest that early changes in the process of ARTR in the first three months after transplantation include interstitial fibrosis [1, 2]. Our results confirmed these observations, and findings of others [6], since relative interstitial volume was in our cases of ARTR significantly increased as compared with controls. Although in our study interstitial volume in ARTR cases included edematous changes, it must be noted that a major part of this compartment was in Masson trichrome staining occupied by connective tissue. Furthermore, our morphometric study showed that interstitial expression of α -SMA was in ARTR patients significantly increased as compared with control group. We observed interstitial staining for α -SMA in a distribution comparable to that of connective interstitial tissue. Moreover, in the study group strong positive correlation existed between interstitial expression of α -SMA and interstitial volume. These findings suggest that interstitial α -SMA positive cells play a role in the development of interstitial fibrosis in ARTR, as they may act as active, extracellular matrix producing cells [22]. Finally, we found interstitial monocytes/macrophages to be significantly more numerous in ARTR than in control group. It has been demonstrated that cytokines such as transforming growth factor β (TGF- β) released by tubular cells and macrophages [21], which plays a key role in the induction of fibrosis, may induce the myofibroblast phenotype in resting fibroblasts [11, 23]. Although our results seem to support this point of view, as CD68+ cells correlated positively with both interstitial expression of α -SMA and interstitial area, the recent study of Nishida et al. suggests that the role of monocytes/macrophages in this process may be very complex [15]. As these authors presented evidence that infiltrating monocytes/macrophages in renal tissue may play a beneficial antifibrotic role, that surprisingly requires the action of angiotensin, the relationships between interstitial CD68+ cells and myofibroblasts need further investigations.

In conclusion, our study suggests that glomerular hypercellularity and mesangial changes are common in ARTR, whereas enhanced interstitial fibrosis confirms a risk of early allograft injury in these cases.

References

1. Abo-Zenah H, Katsoudas S, de Takats D, Shortland J, Brown CB, El-Nahas AM: Early progressive interstitial fibrosis in human renal allografts. *Clin Nephrol* 2002, 57, 9-18.
2. Abo-Zenah H, Katsoudas S, Wild G, de Takats D, Shortland J, Brown CB, El-Nahas AM: Early human renal allograft fibrosis: Cellular mediators. *Nephron* 2002, 91, 112-119.

3. *Alpers CE, Hudkins KL, Gown AM, Johnson RJ*: Enhanced expression of 'muscle specific' actin in glomerulonephritis. *Kidney Int* 1992, 41, 1134-1142.
4. *Andersen CB*: Acute kidney graft rejection morphology and immunology. *APMIS Suppl* 1997, 67, 1-35.
5. *Axelsen RA, Seymour AE, Mathew TH, Canny A, Pascoe V*: Glomerular transplant rejection: a distinctive pattern of early graft damage. *Clin Nephrol* 1985, 23, 1-11.
6. *Baboolal K, Jones GA, Janezic A, Griffiths DR, Jurewicz WA*: Molecular and structural consequences of early renal allograft injury. *Kidney Int* 2002, 61, 686-696.
7. *Baltzan MA, Shoker AS, Baltzan RB, George D*: HLA-identity: long-term renal graft survival, acute vascular, chronic vascular, and acute interstitial rejection. *Transplantation* 1996, 61, 881.
8. *Bhathena DB*: Glomerular size and the association of focal glomerulosclerosis in long-surviving human renal allografts. *J Am Soc Nephrol* 1993, 4, 1316-1326.
9. *Cecka JM, Cho YW, Terasaki PI*: Analyses of the UNOS Scientific Renal Transplant Registry at three years: early events affecting transplant success. *Transplantation* 1992, 53, 59-64.
10. *Colvin RB*: Renal transplant pathology. In: *Heptinstall's Pathology of the Kidney*. Vol 2. Janette. JC, Olson JL, Schwartz MM, Silva FG, eds. Lippincott-Raven, Philadelphia, New York 1998, pp 1409-1540.
11. *Eghbali M, Tomek R, Woods C, Bhambi B*: Cardiac fibroblasts are predisposed to convert into myocyte phenotype: specific effect of transforming growth factor β . *Proc Natl Acad Sci USA* 1991, 88, 795-799.
12. *MacPherson BR, Leslie KO, Lizaso KV, Schwarz JE*: Contractile cells of the kidney in primary glomerular disorders: an immunohistochemical study using an anti-alpha-smooth muscle actin monoclonal antibody. *Hum Pathol* 1993, 24, 710-716.
13. *Messias NC, Eustace JA, Zachary AA, Tucker PC, Charney D, Racusen LC*: Cohort study of the prognostic significance of acute transplant glomerulitis in acutely rejecting renal allografts. *Transplantation* 2001, 72, 655-660.
14. *Nickeleit V, Vamvakas EC, Pascual M, Poletti BJ, Colvin RB*: The prognostic significance of specific arterial lesions in acute renal allograft rejection. *Am J Soc Nephrol* 1998, 9, 1301-1308.
15. *Nishida M, Fujinaka H, Matsusaka T, Price J, Kon V, Fogo AB, Davidson JM, Linton MF, Fazio S, Homma T, Yoshida H, Ishikawa I*: Absence of angiotensin II type 1 receptor in bone marrow-derived cells is detrimental in the evolution of renal fibrosis. *J Clin Invest* 2002, 110, 1859-1868.
16. *Olsen S, Spencer E, Cockfield S, Marcussen N, Solez K*: Endocapillary glomerulitis in the renal allograft. *Transplantation* 1995, 59, 1421-1425.
17. *Ozdemir BH, Demirhan B, Gungen Y*: The presence and prognostic importance of glomerular macrophage infiltration in renal allografts. *Nephron* 2002, 90, 442-446.
18. *Pascoe MD, Marshall SE, Welsh KI, Fulton LM, Hughes DA*: Increased accuracy of renal allograft rejection diagnosis using combined perforin, granzyme B, and FAS ligand fine-needle aspiration immunocytology. *Transplantation* 2000, 69, 2547-2553.
19. *Pilmore HL, Painter DM, Bishop GA, McCaughan GW, Eris JM*: Early up-regulation of macrophages and myofibroblasts: a new marker for development of chronic renal allograft rejection. *Transplantation* 2000, 69, 2658-2662.
20. *Racusen LC, Solez K, Colvin RB, Bonsib SM, Castro MC, Cavallo T, Croker BP, Demetris AJ, Drachenberg CB, Fogo AB, Furness P, Gaber LW, Gibson IW, Glotz D, Goldberg JC, Grande J, Halloran PF, Hansen HE, Hartley B, Hayry PJ, Hill CM, Hoffman EO, Hunsicker LG, Lindblad AS, Marcussen N, Mihatsch MJ, Nadasdy T, Nickerson P, Olsen TS, Papadimitriou JC, Randhawa PS, Rayner DC, Roberts I, Rose S, Rush D, Salinas-Madrigal L, Salomon DR, Sund S, Taskinen E, Trepkov K, Yamaguchi Y*: The Banff 97 working classification of renal allograft pathology. *Kidney Int* 1999, 55, 713-723.
21. *Roberts ISD, Burrows C, Shanks JH, Venning M, McWilliam LJ*: Interstitial myofibroblasts: predictors of progression in membranous glomerulopathy. *J Clin Pathol* 1997, 50, 123-127.
22. *Strutz F*: The fibroblast - a (trans-)differentiated cell? *Nephrol Dial Transplant* 1995, 10, 1504-1506.
23. *Strutz F*: Novel aspects of renal fibrogenesis. *Nephrol Dial Transplant* 1995, 10, 1526-1532.
24. *Weibel ER*: Point counting methods. In: *Stereological Methods*. Vol 1. Weibel ER, ed. Academic Press, London, New York, Toronto, Sydney, San Francisco 1979, pp 101-159.

Address for correspondence and reprint requests to:

Prof. M. Danilewicz, M.D., Ph.D.
 Department of Nephropathology
 Medical University
 Czechosłowacka 8/10, 92-216 Łódź