

Magdalena Jakubiak-Wielganowicz¹, Robert Kubiak², Jacek Sygut⁴, Lech Pomorski³,
Radziszlaw Kordek²

Usefulness of Galectin-3 Immunohistochemistry in Differential Diagnosis between Thyroid Follicular Carcinoma and Follicular Adenoma

¹Department of Pathology, Copernicus Memorial Hospital,

²Department of Oncology,

³Department of Endocrinological Surgery, Medical University, Łódź

⁴Department of Pathology, Holy Cross Cancer Center, Kielce

Galectin-3 was primarily reported to be a marker distinguishing thyroid adenomas and carcinomas. To check the usefulness of anti-galectin-3 immunohistochemistry, we studied its expression in 42 follicular adenomas and 42 follicular carcinomas. Eight cases out of 42 follicular adenomas (19%) presented focal or diffuse galectin-3 immunorexpression. From 42 cases of follicular carcinomas, six cases did not present galectin-3 immunopositivity at all. Three of these cases were widely invasive (one with focal anaplastic feature and one oxyphilic), and three other ones were minimally invasive. Two other carcinoma cases had only small foci positive with galectin-3 antibody, thirteen cases presented positivity mostly restricted to peripheral part of the tumor and 21 cases possessed diffuse, strong reaction. Two adenomas presented galectin-3 positive foci, and these cells had light nuclear changes superficially suggesting follicular variant of papillary carcinoma, mostly because of nuclear clearing. In these tumors, adenoma diagnosis was supported by experts, but we can not exclude that they represent early phase of malignisation, although such theory needs to be proved. Our study does not allow to use galectin-3 as a highly specific marker, differentiating between follicular benign and malignant tumor, although it may be used as an additive tool.

Introduction

Minimally invasive follicular thyroid carcinoma may be easily diagnosed in cases meeting criteria of minimal but entire thickness capsular and/or vascular invasion. Unfortunately, there are also cases where these criteria are not clearly recognized and additional data would be important, as it may happen with not representative surgical specimen. What shows even to be more important, preoperative fine needle cytology cannot differentiate between some hyperplastic nodules, adenomas and carcinomas. Some important prob-

lems may occur in differentiating between follicular variant of papillary thyroid carcinoma and follicular adenomas with some nuclear changes suggesting this type of cancer. All these diagnostic problems create a need for immunohistochemical markers differentiating these tumors. Recently, a few such markers were proposed: galectin-1, galectin-3, CD26, cytokeratin 19, HBME-1 and RET [1 - 4, 8, 19].

In 1995, Xu and al. reported differences in expression of galectin 1 and 3 between thyroid malignancies and benign thyroid tumors [24], and the usefulness of galectin-3 status was supported by consecutive studies [7, 17].

Galectin-3 is a member of lectins binding beta-galactosides and this glycoprotein plays an important role in organogenesis. It is also expressed in many neoplastic lesions having a close relation to tumor progression, invasion and metastasis formation [10, 14, 15, 17, 20]. Galectin-3 works as redundant pre-mRNA splicing factor, regulates the cell cycle and apoptosis, being either anti-apoptotic or proapoptotic [see 13 for references].

Alterations in galectin-3 expression were found in a variety of human tumors: thyroid cancer [1, 3, 12, 16], breast cancer [9], melanoma [18], colon cancer [11, 21], pancreas carcinoma [22] and in gastric and skin cancers, lymphomas and glioblastomas [see 6 for references]. Reports concerning the usefulness of galectin-3 immunopositivity in differentiating benign and malignant thyroid tumors are slightly conflicting. While some authors reported galectin-3 as a very sensitive marker of follicular malignancy [10, 12], others did not. Beesley et al. found this lectin in all follicular carcinomas but also in 1 out of 20 adenomas, and in three out of eight nodular goitres [3]. Aratake et al. found galectin-3 in five out of six follicular carcinomas and two out of 14 adenomas [1]. Similarly, Nascimento et al. reported galectin-3 positivity in 11 out of 14 carcinomas and 1 out of 9

adenomas [14]. Others found its expression in 4 out of 52 follicular adenomas [20].

The aim of this study was to establish the usefulness of galectin-3 immunohistochemistry in differentiating benign and malignant follicular thyroid tumors.

Material and Methods

We examined 42 consecutive follicular carcinomas and 42 adenomas, removed by the Clinics of Endocrinological Surgery, Medical University in Łódź, primarily diagnosed in the Department of Pathology, Copernicus Memorial Hospital and with diagnoses confirmed according to the criteria provided by the WHO classification.

Subtypes of adenomas were: one trabecular adenoma, two oncocytic adenomas, 39 follicular adenomas (some of them with focal oncocytic change). Among carcinomas - 26 cases presented minimal invasion and 16 cases were widely invasive, 25 carcinomas were of oncocytic subtype, and 4 were of high grade. Representative slides of every single tumor were immunostained with anti-galectin-3 antibody (Dako) using En-Vision system (Dako). Slides were pre-treated in microwave in citrate buffer, pH 6.0.

Other authors [12] used semiquantitative scoring method for evaluation of galectin-3 immunopositivity, but in our opinion such scoring is not useful for the standard of "everyday" practice. As 0, we regarded cases without galectin-3 expression, as 1+ - with only small foci of positive cells - less than 10% of the tumor mass (Fig. 1E), as 2+ - tumors with more intense but still focal immunopositivity, both inside the tumor or on the periphery (10 - 50% of cells; Figs. 1B and C), and as 3+ - cases with diffuse immunopositivity where more than 50% of cells were galectin-3 immunopositive (with any intensity; Fig. 1A).

Results

Galectin-3 expression in follicular adenomas

Detailed results are presented in Table 1. Four cases of follicular adenoma presented diffuse galectin-3 immunopositivity regarded as 3+ (Fig. 1D). Four next cases had small strongly immunostained foci, located mostly on the periphery of the tumor (Fig. 1C), but also within the tumor mass (Fig. 1F). Thus, 8 out of 42 follicular adenomas (19%) presented galectin-3 immunopositivity.

Two adenomas with 2+ score possessed small foci with nuclear changes suggestive, but not diagnostic, for papillary carcinoma (some grooving and focally lighter nuclei) (Fig. 1F). These cases were reviewed additionally by four experts in thyroid pathology, and still regarded as adenomas.

One out of four adenomas with galectin-3 expression regarded as score 3+ presented diffuse oncocytic change. Similarly, immunopositive foci in two other adenomas were also mostly connected with oncocytic metaplasia (Fig. 1D).

TABLE 1

Galectin-3 immunopositivity in thyroid follicular adenomas and follicular carcinomas

Tumor/score	0	1+	2+	3+	total
Adenoma	36	0	4	4	42
Carcinoma	6	2	13	21	42

TABLE 2

Galectin-3 immunopositivity in histologic subtypes and stage of follicular carcinoma

Types/ pTNM/scores	0	1+	2+	3+	Total
Oncocytic	1	0	7	17	25
Follicular - low grade	4	2	6	1	13
High grade (+insular)	1	0	0	3	4
Total	6	2	13	21	42
Minimally invasive	3	2	7	14	26
Widely invasive	3	0	6	7	16
Total	6	2	13	21	42
PT2	2	1	6	13	22
PT3	1	1	3	7	12
PT4	3	0	4	1	8
Total	6	2	13	21	42

One adenoma had thyroid tissue inside small capsular vessel suggestive for vascular invasion but not meeting the criteria of malignancy (not connected with the vessel wall and not covered with the endothelium) - this case was galectin-3 negative.

Galectin-3-immunopositivity was observed not only in adenoma tissue but it also seldom occurred in inactive follicles around the tumor. Moreover, galectin-3 immunopositivity was not restricted to thyrocytes - positive staining was also observed in histiocytes, lymphoid germinal centers, fibroblasts, nerve fibers and in the wall of small vessels.

Galectin 3 expression in follicular carcinomas

Detailed data are presented in Table 2. Not all, but 38 out of 42 cases of follicular carcinoma presented galectin-3 immunopositivity, and the intensity of staining widely varied: majority (21 out of 38) presented strong diffuse immunopositivity (Fig. 1A). In 13 out of 42 cases - staining was restricted to the periphery of the tumor, and in two carcinomas - only a very small foci were found (Fig. 1E). Six evident carcinomas were completely negative. Half of galectin-3 negative tumors were widely in-

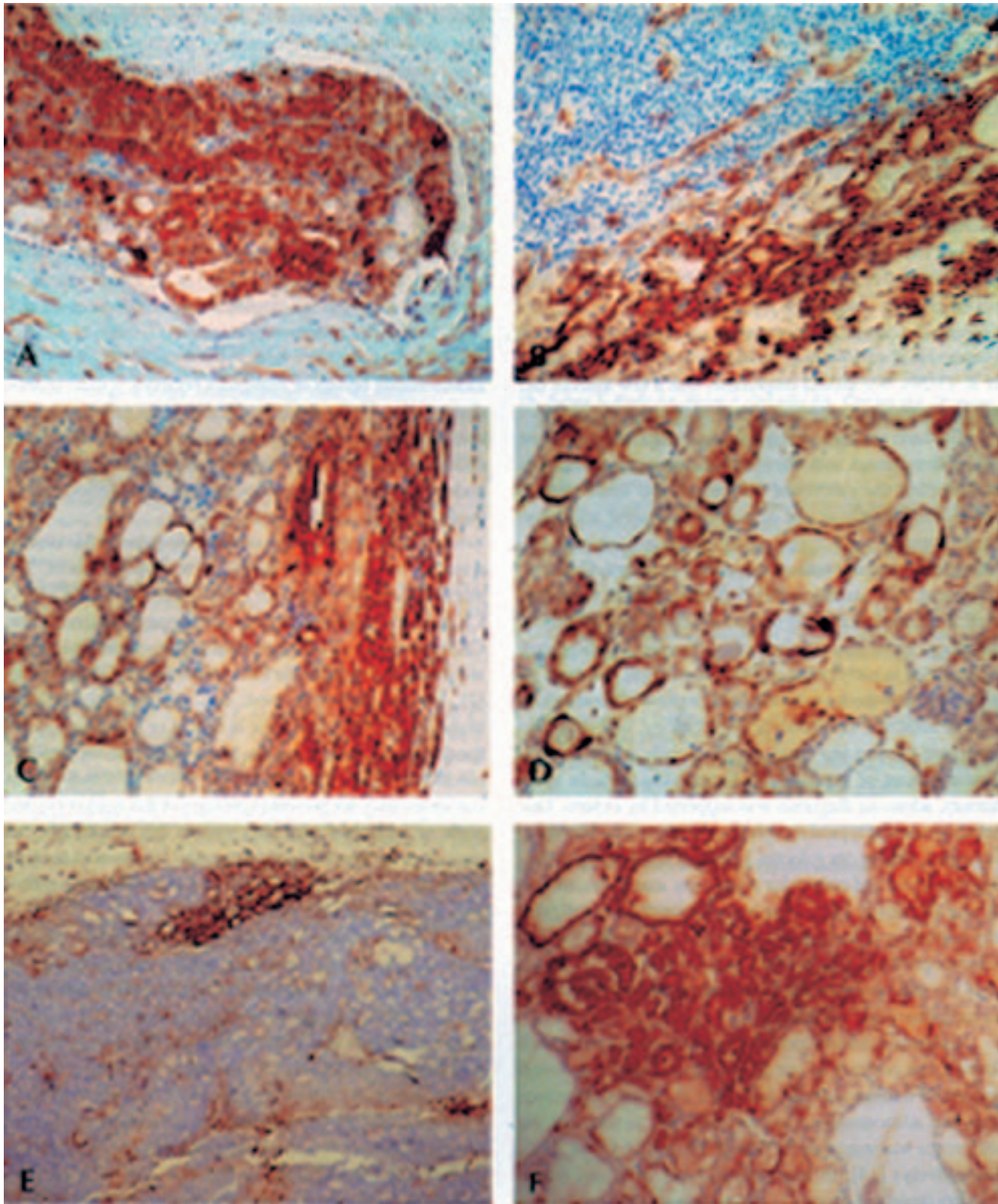


Fig. 1. Galectin-3 expression in thyroid follicular tumors. A. Strong 3+ reaction in vascular invasion of follicular carcinoma. B. Follicular carcinoma with galectin-3 expression restricted to the periphery of the tumor, regarded as 2+. C. Identical pattern of immunopositivity in follicular adenoma. D. Normofollicular adenoma with diffuse galectin-3 immunopositivity. E. Small focus of galectin-3 immunopositivity in minimally invasive carcinoma. F. Adenoma with small galectin-3 positive focus with some poorly developed features suggestive for papillary carcinoma (nuclear chromatin clearing and grooving), but not diagnostic for cancer.

vasive, one was of high-grade, and the majority were clinically advanced.

Discussion

In our study we obtained galectin-3 immunopositivity in the majority of follicular carcinomas and in a part of follicular adenomas. Thus, intense galectin-3 expression strongly suggests malignancy, while absence of this marker can not exclude carcinoma. These results are concordant with a majority of previous reports, although they are less optimistic than some of the reports [3, 8, 12, 14, 15, 17, 20]. Galectin-3-positive adenomas were also reported by others: Gasbarri et al. (1/37 cases), Aratake et al. (2/14) and Orlandi et al. (3/29). We should emphasize, that a few authors did not find galectin-3 expression in any adenoma [7, 10, 24].

Gasbarri et al. observed galectin-3 expression in three out of five tumors with minimal capsular penetration, thus not meeting the criteria of carcinoma and these authors suggested, that at least part of galectin-3-positive adenomas may represent an incipient malignant transformation [8]. This theory was also recently supported by others. Coli et al. suggested, that small galectin-3 positive foci in otherwise typical adenoma may represent poorly developed features of papillary carcinoma (mainly nuclear clearing) and these may be regarded as early phase of malignisation [5]. We have no proof for such theory - some of our positive adenomas had typical follicular or oncocytic morphology, and only two presented light nuclear changes superficially suggesting follicular variant of papillary carcinoma (Fig. 1F). In these tumors, adenoma diagnosis was supported by experts. One another case had typical morphology of trabecular adenoma. As stated, among our galectin-3 positive adenomas, excluding oncocytic and trabecular ones, were also "normal" follicular adenomas. Thus, there are not enough data to suggest the beginning of malignancy in these cases, and galectin-3 immunopositivity can not be simply explained. Truly, one may say that observes "incipient malignant transformation" in each one single adenoma!

Galectin-3 immunopositivity of oncocytic cells is well known, but contrary to our study, Nascimento et al. found galectin-3 immunostaining less often in oncocytic carcinomas and adenomas than in pure follicular tumors, but the difference was minimal (59% vs 78.5% and 11.1% vs 7.1%, respectively) [14]. In our study, 17 out of 25 oncocytic cancers presented strong (3+) immunopositivity, while only one out of 13 of "common" follicular carcinomas presented so strong reaction. These last tumors presented galectin-3 expression mainly on the periphery (see Table 2 and figures).

According to recent data [17, 20], the absence of galectin-3 expression occurred predominantly in high-grade follicular carcinomas. Our study does not support such observation - three of our cases were positive, while one was

almost completely negative. Moreover, follicular carcinomas presented higher percentage of galectin-3 expression at lower stage (T2), and cancers of higher stage less often possessed galectin-3 immunopositivity.

Following the first optimistic reports, the studies analyzing the usefulness of estimation of galectin-3 expression in cytological, preoperative material were performed [8, 10, 15, 17, 20]. The results were similar to those obtained with histology: almost all (or all) cases of carcinoma presented immunopositivity, while the majority of benign tumors were negative. For instance, Saggiorato et al. found galectin-3 immunopositivity in 16 cytological materials from 17 biopsied minimally invasive carcinomas. Gasbarri et al. suggest, that cases diagnosed cytologically as "lesions of indeterminate benign or malignant behavior" (what is often diagnosed as "follicular tumor"), which are galectin-3-positive, should be surgically removed. We think, that after taking into account the possibility of only focal expression and very high specificity and sensitivity, this method may be used only as an additive tool.

As we mentioned before, not only galectin 3 is used as a marker for differential diagnosis of thyroid tumors. The markers used more often are cytokeratins CK17, CK19 and CK20, shown to be the most specific for papillary carcinoma. CK19 occurs in all subtypes of papillary carcinoma, and is not expressed in follicular tumors and hyperplastic nodules [2]. Further studies showed, that although focal CK-19 immunopositivity may occur in benign or follicular lesions, the diffuse positivity seems to be characteristic for papillary carcinoma [4]. Unfortunately, 20 - 40% of cases of this carcinoma may not present expression of this marker [4], and some of adenomas may also possess this cytokeratin, but never in more than 75% of tumor cells [19]. Parallel analysis of CK19 and galectin-3 seems to be a useful tool in pathological evaluation of thyroid tumors [3].

Between remaining markers, RET and HBME-1 are the most specific in differentiating benign and malignant tumors, but they are not specific for given type of cancer [4]. CD26/DPPIV gives similar results to galectin-3 [1]. Another proposed antigen was CD44v6 isoform, but it is clearly less sensitive and specific [8, 23, our data not shown].

In summary, although galectin-3 was not proven to be highly specific or sensitive for given type of thyroid tumor, it seems to be a valuable tool helping in diagnosis of difficult thyroid tumors, but can not be used as a specific marker. As discussed in literature, galectin-3 may be also helpful in preoperative diagnosis of tumors diagnosed cytologically as "follicular tumor, suspected for neoplasm". As galectin-3 may be present in some adenomas, it does not seem to be a tool in differentiating between follicular variant of papillary carcinoma and follicular adenoma - strong expression of cytokeratin 19 is probably more useful marker.

References

1. Aratake Y, Umeki K, Kiyoyama K, Hinoura Y, Sato S, Ohno A, Kuribayashi T, Hirai K, Nabeshima K, Kotani T: Diagnostic utility of galectin-3 and CD26/DPPIV as preoperative diagnostic markers for thyroid nodules. *Diagn Cytopathol* 2002, 26, 366-372.
2. Baloch ZW, Abraham S, Roberts S, LiVolsi VA: Differential expression of cytokeratins in follicular variant of papillary carcinoma, an immunohistochemical study and its diagnostic utility. *Hum Pathol* 1999, 30, 1166-1171.
3. Beesley MF, McLaren KM: Cytokeratin and galectin-3 immunohistochemistry in the differential diagnosis of solitary thyroid nodules. *Histopathology* 2002, 41, 236-243.
4. Cheung CC, Ezzat S, Freeman JL, Rosen IB, Asa SL: Immunohistochemical diagnosis of papillary thyroid carcinoma. *Mod Pathol* 2001, 14, 338-342.
5. Coli A, Bigotti G, Zuchetti F, Massi G: Galectin 3, a marker of well differentiated thyroid carcinoma, is expressed in thyroid nodules with cytological atypia. *Histopathology* 2002, 40, 80-87.
6. Cvejić D, Savin S, Golubović S, Paunović I, Tatic S, Havelka M: Galectin-3 and carcinoembryonic antigen expression in medullary thyroid carcinoma, possible relation to tumor progression. *Histopathology* 2000, 37, 530-535.
7. Fernandez PL, Merino MJ, Gomez M, Campo E, Medina T, Castronovo V, Sanjuan X, Cardesa A, Liu F-T, Sobel ME: Galectin-3 and laminin expression in neoplastic and non-neoplastic thyroid tissue. *J Pathol* 1997, 181, 80-86.
8. Gasbarri A, Martegani MP, Prete F, Lucante T, Natali PG, Bartolazzi A: Galectin-3 and CD44v6 isoforms in the preoperative evaluation of thyroid nodules. *J Clin Oncol* 1999, 17, 3494-3502.
9. Idikio H: Galectin-3 expression in human breast carcinoma, correlation with cancer histologic grade. *Int J Oncol* 1998, 12, 1287-1290.
10. Inohara H, Honjo Y, Yoshii T, Akahani S, Yoshida J, Hattori K, Okamoto S, Sawada T, Raz A, Kubo T: Expression of galectin-3 in fine-needle aspirates as a diagnostic marker differentiating benign from malignant thyroid neoplasms. *Cancer* 1999, 85, 2475-2484.
11. Irimura T, Matsushita Y, Sutton R: Increased content of an endogenous lactose-binding lectin in human colorectal carcinoma progressed to metastatic stages. *Cancer Res* 1991, 51, 387-393.
12. Kawachi K, Matsushita Y, Yonezawa S, Nakano S, Shirao K, Natsugoe S, Sueyoshi K, Aikou T, Sato E: Galectin-3 expression in various thyroid neoplasms and its possible role in metastasis formation. *Hum Pathol* 2000, 31, 428-433.
13. Liu F, Patterson R, Wang J: Intracellular functions of galectins. *Biochim Biophys Acta* 2002, 1572, 263-273.
14. Nascimento MC, Bisi H, Alves VA, Longatto-Filho A, Kanamura CT, Medeiros-Netto G: Differential reactivity for galectin-3 in Hürtle cell adenomas and carcinomas. *Endocrinol Pathol* 2001, 12, 275-279.
15. Niedobitek C, Niedobitek F, Lindenberg G, Bachler B, Neudeck H, Zuschneid W, Hopfenmüller W: Expression of galectin-3 in thyroid gland and follicular cell tumors of the thyroid. A critical study of its possible role in preoperative differential diagnosis. *Pathologie* 2001, 22, 205-213.
16. Niedziela M, Maceluch J, Korman E: Galectin-3 is not an universal marker of malignancy in thyroid disease in children and adolescents. *J Clin Endocrinol Metab* 2002, 87, 4411-4415.
17. Orlandi F, Saggiorato E, Pivano G, Puligheddu B, Termine A, Cappia S, Giuli P, Angeli A: Galectin-3 is a presurgical marker of human thyroid carcinoma. *Cancer Res* 1998, 58, 3015-3020.
18. Rye PD, Fodstad O, Emilsen E: Invasion potential and N-acetylgalactosamine expression in a human melanoma model. *Int J Cancer* 1998, 75, 609-614.
19. Sahoo S, Hoda SA, Rosai J, DeLellis RA: Cytokeratin 19 immunoreactivity in the diagnosis of papillary thyroid carcinoma, a note of caution. *Am J Clin Pathol* 2001, 116, 696-702.
20. Saggiorato E, Cappia S, Giuli P, Mussa A, Pancani G, Caraci P, Angeli A, Orlandi F: Galectin-3 as a presurgical immunocytodiagnostic marker of minimally invasive follicular thyroid carcinoma. *J Clin Endocrinol Metab* 2001, 86, 5152-5158.
21. Schoepner H, Raz A, Ho SB: Expression of an endogenous galactose-binding lectin correlates with neoplastic progression in the colon. *Cancer* 1975, 75, 2818-2826.
22. Shimamura T, Sakamoto M, Ino Y, Shimada K, Kosuge T, Sato Y, Tanaka K, Sekihara H, Hirohashi S: Clinicopathological significance of galectin-3 expression in ductal adenocarcinoma of the pancreas. *Clin Cancer Res* 2002, 8, 2570-2575.
23. Takano T, Sumizaki H, Nakano K, Kuma K, Amino N: Increased expression of CD44 variants in differentiated thyroid cancers. *Jpn J Cancer Res* 1996, 87, 1245-1250.
24. Xu X-C, el-Naggar AK, Lotan R: Differential expression of galectin-3 and galectin-1 in thyroid tumors. *Am J Pathol* 1995, 147, 815-822.

Address for correspondence and reprint requests to:

Prof. R. Kordek, M.D.
 Department of Oncology
 Paderewskiego 4, 93-509 Łódź
 Phone: 42 6895780
 Fax: 42 6895422
 e-mail: rkordek@csk.am.lodz.pl